

## CONTINUING MEDICAL EDUCATION ΣΥΝΕΧΙΖΟΜΕΝΗ ΙΑΤΡΙΚΗ ΕΚΠΑΙΔΕΥΣΗ

---

### Hematology-Cell Morphology – Case 25

- Blasts without granulation
- Similar morphology to ALL L2
- Diagnosis is impossible with only morphological criteria
- Indications of commitment to the granulocytic series by immunophenotyping
- Negative lymphoid indices
- Positive granulocytic series indices

Blasts in the peripheral blood and bone marrow (figures 1 to 15).

Myeloperoxidase reaction negative under light microscope (fig. 16), while the staining is positive by the electronic microscope. Special attention to the blasts which may be positive in platelet peroxidase (AML M7).

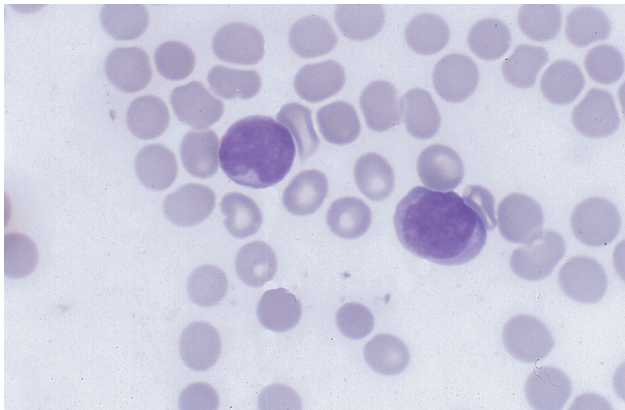


Figure 1

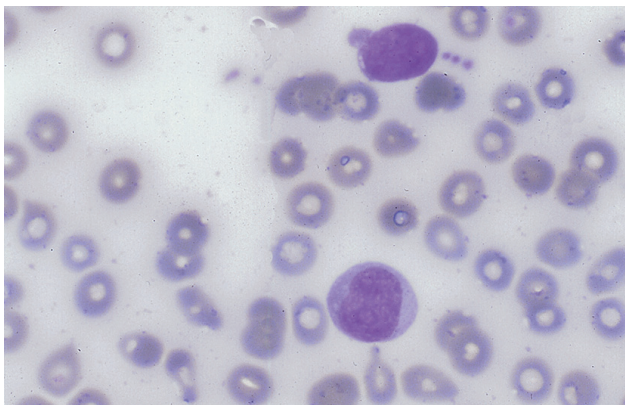


Figure 2

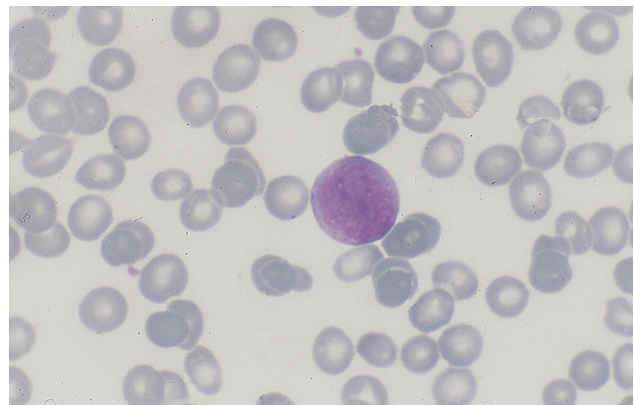


Figure 3

---

ARCHIVES OF HELLENIC MEDICINE 2024, 41(5):716–718  
ΑΡΧΕΙΑ ΕΛΛΗΝΙΚΗΣ ΙΑΤΡΙΚΗΣ 2024, 41(5):716–718

---

**J.V. Asimakopoulos,  
L. Papageorgiou,  
J. Drandakis,  
I. Vasilopoulos,  
A. Kopsaftopoulou,  
A. Piperidou,  
A. Machairas,  
A. Georgopoulou,  
A. Karapaschalidis,  
M.A. Lefaki,  
A. Liaskas,  
C. Zerzi,  
E. Plata,  
P. Tsaftaridis,  
M.P. Siakantaris,  
T.P. Vassilakopoulos,  
M.K. Angelopoulou,  
J. Meletis**

---

*School of Medicine, National and  
Kapodistrian University of Athens,  
"Laiko" General Hospital, Athens, Greece*

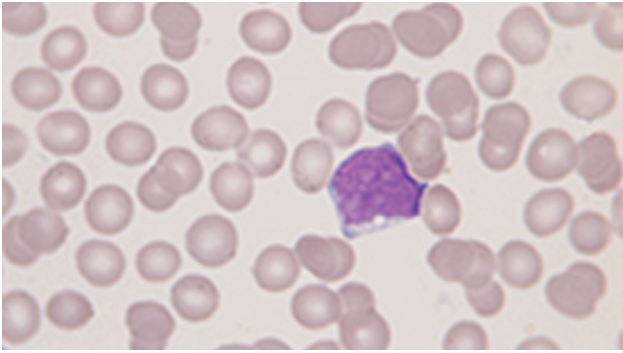


Figure 4

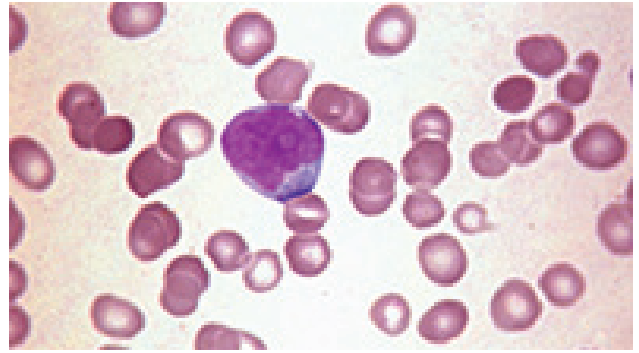


Figure 8

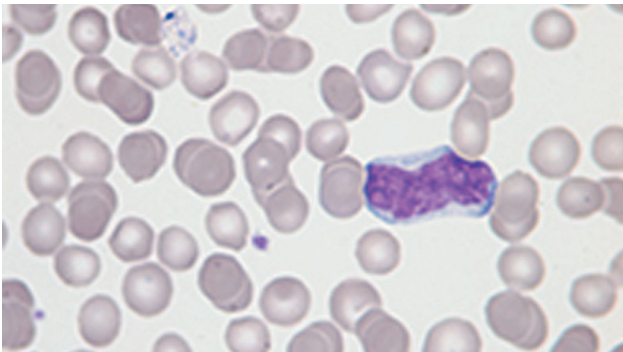


Figure 5

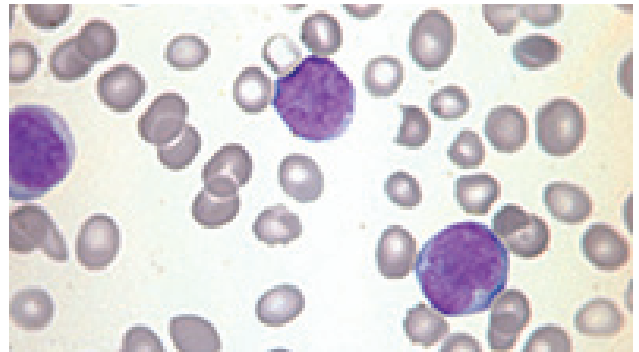


Figure 9

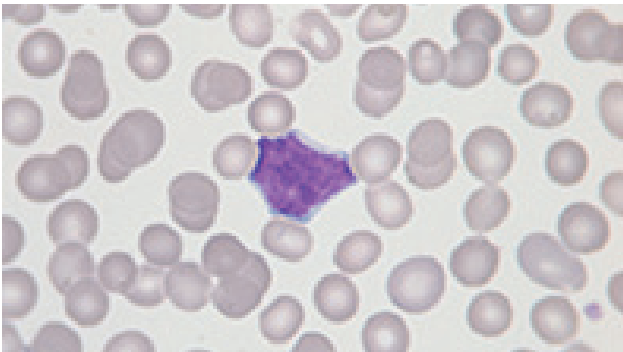


Figure 6

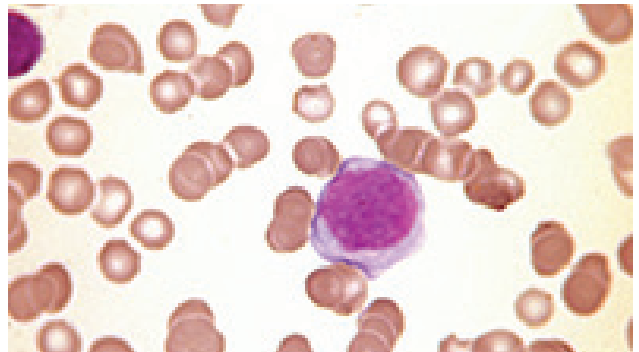

Figure 10

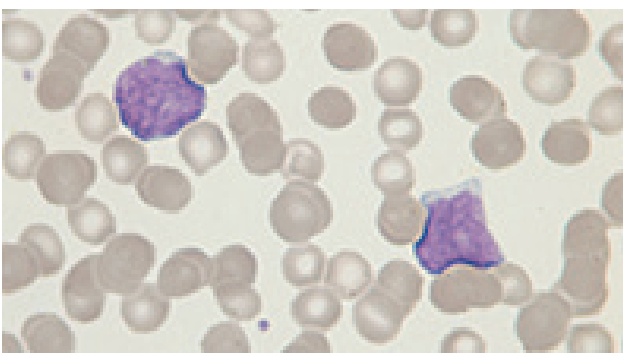


Figure 7

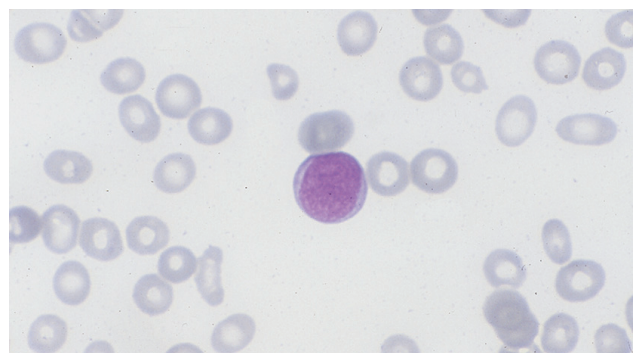


Figure 11

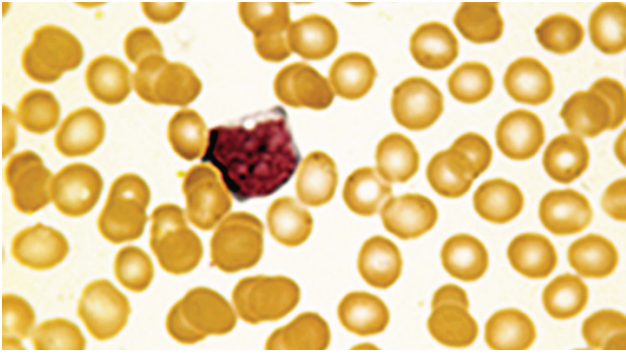


Figure 12

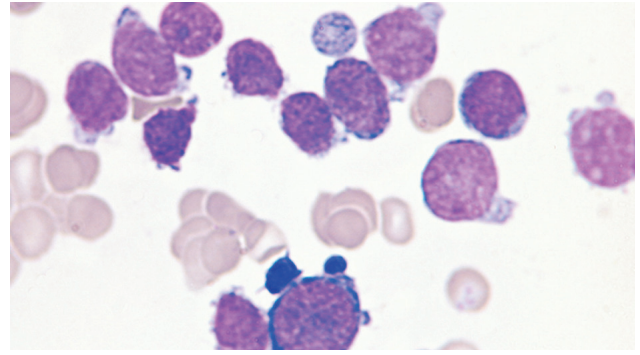


Figure 15

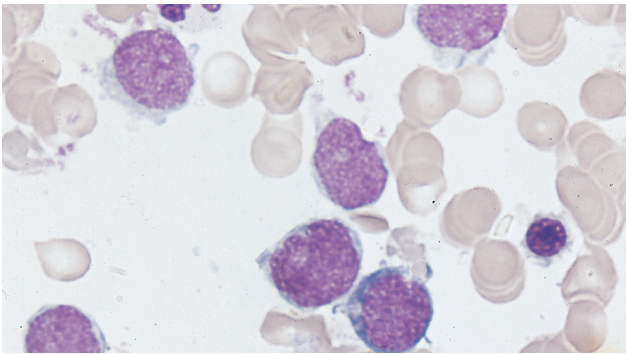


Figure 13

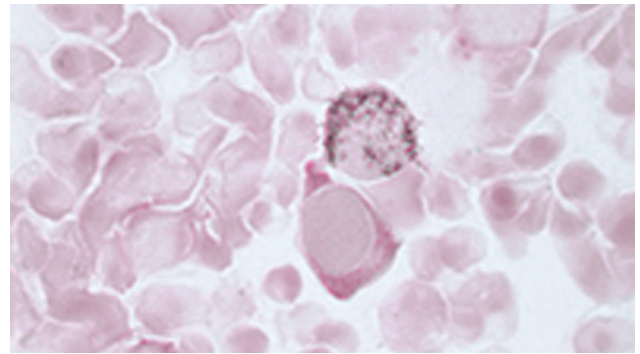


Figure 16

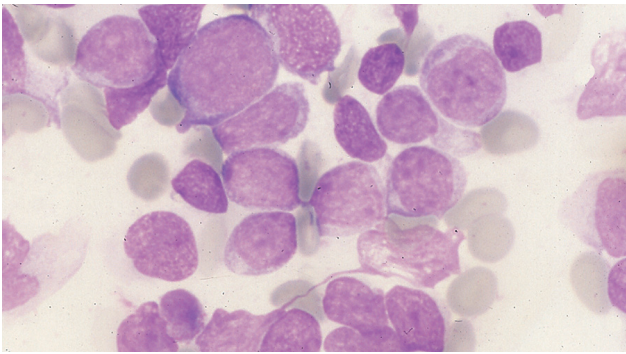


Figure 14

References

- 1. MELETIS J. *Atlas of hematology*. 3rd ed. Nireas Publ Inc, Athens, 2009:322–325

Corresponding author:

J. Meletis, School of Medicine, National and Kapodistrian University of Athens, "Laiko" General Hospital, 115 27 Athens, Greece  
 e-mail: imeletis@med.uoa.gr