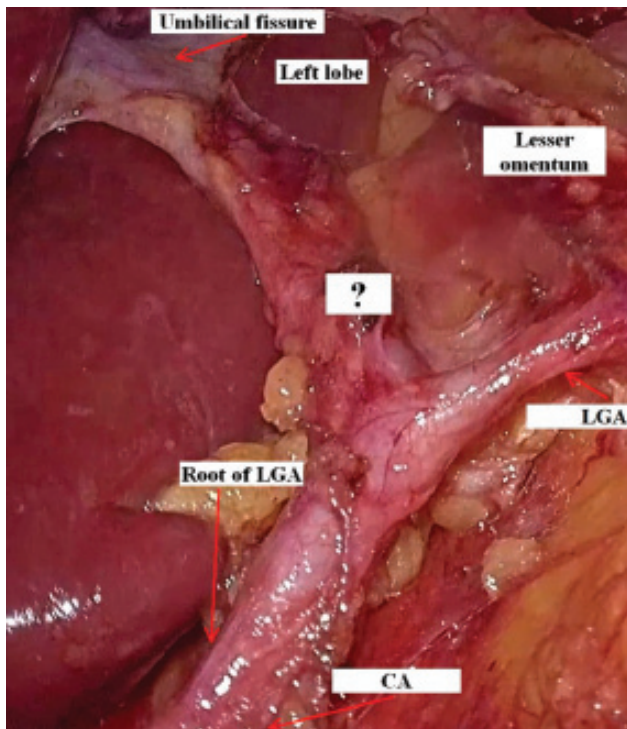


## CONTINUING MEDICAL EDUCATION ΣΥΝΕΧΙΖΟΜΕΝΗ ΙΑΤΡΙΚΗ ΕΚΠΑΙΔΕΥΣΗ

### Surgery Quiz – Case 44

A 73-year-old female patient with a history of stage I arterial hypertension under perindopril 10 mg once daily, referred to our surgical department for management of a moderate differentiated cT3cN1-2M0 middle third adenocarcinoma of the stomach at the lesser curvature. The patient submitted to open total gastrectomy with D2 lymphadenectomy, complete omentectomy and antecolic Roux-en-Y esophagojejunostomy using a 25 mm circular stapler. Postoperative course was uneventful. Histology of the surgical specimen revealed a T3, N2 (6/39), M0 (P0, CY0, H0) moderate differentiated ly3, v2 adenocarcinoma of the middle-third after a R0 (PM0, DM0) resection. During lymph node dissection at the celiac axis, a vascular structure originating from the left gastric artery was observed, as shown in figure 1.

Which is this central arterial structure?



**Figure 1.** Intraoperative view of the surgical field during lymph node dissection at the root of left gastric artery (LGA) (CA: Celiac axis; question mark: Which is this central artery originating from the LGA?).

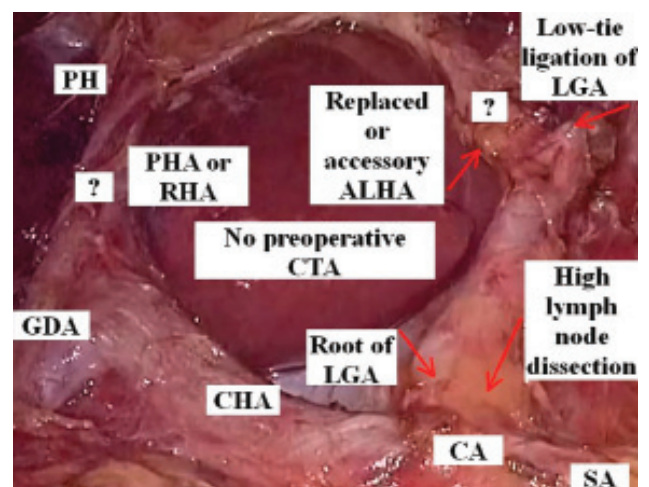
ARCHIVES OF HELLENIC MEDICINE 2023, 40(1):141–142  
ΑΡΧΕΙΑ ΕΛΛΗΝΙΚΗΣ ΙΑΤΡΙΚΗΣ 2023, 40(1):141–142

K. Boulas,  
M. Nathanailidou,  
K. Sitaridis,  
G. Sourtse,  
A. Hatzigeorgiadis

Department of General Surgery, General  
Hospital of Drama, Drama, Greece

#### Comments

At or near the porta hepatis, the proper hepatic artery divides into two branches, the right and left hepatic artery. The most frequent left hepatic arterial variations are: (a) The replaced left hepatic artery, when the aberrant artery does not originate from an orthodox position and supplies only that part of the liver due to the absence of a normal liver artery; and (b) the accessory left hepatic artery, when the aberrant artery supplies part of the liver jointly with a normal artery. The replaced and accessory aberrant left hepatic artery (ALHA) had a prevalence of 8.3% and 5.6%, respectively. The ALHA plays a very important role in the hemodynamic of the left liver circulation. Usually, a transient postoperative alteration of liver function tests (SGOT, SGPT, TBIL) is reported in ALHA ligation patients compared to ALHA preservation patients without significant differences in the number of harvested lymph nodes, postoperative



**Figure 2.** Intraoperative view of the surgical field after low-tie ligation and high dissection of the left gastric artery (LGA) for preservation of the replaced or accessory aberrant left hepatic artery (PH: Porta hepatis; PHA: Proper hepatic artery; RHA: Right hepatic artery; GDA: Gastroduodenal artery; CHA: Common hepatic artery; CA: Celiac axis; ALHA: Aberrant left hepatic artery).

morbidity and mortality. Collateralization between intrahepatic and phrenic arteries preserve the left liver lobe from ischemia and begins the first 10 hours after arterial ligation. Liver necrosis of the left lobe is an extremely rare complication; only patients with chronic liver diseases are the most susceptible to ischemia caused by ALHA ligation.

In the present patient, a central vascular structure at the root of left gastric artery was recognized during lymph node dissection around the celiac axis. The present artery represented an aberrant left hepatic artery. As the ALHA was not recognized in preoperative imaging, a distinction between a replaced and accessory artery could not be made intraoperatively. In order to avoid ischemic liver complications, low tie ligation of the left gastric artery distal to the origin of the ALHA along with high lymph node dissection around the root of left gastric artery and celiac axis performed, as shown in figure 2. In conclusion, an ALHA is a common finding during gastrectomy with D2 lymphadenectomy. Preoperative evaluation with computed tomography (CT) angiography is important to help surgeons recognize this anatomical variation, avoid intraoperative ALHA injury and reduce postoperative morbidity. Low ligation plus

high dissection of the left gastric artery is proposed when an aberrant left hepatic artery is present in order to avoid transient ischemic liver complications during D2 gastrectomy for gastric cancer.

## References

1. CIROCCHI R, D'ANDREA V, AMATO B, RENZI C, HENRY BM, TOMASZEWSKI KA ET AL. Aberrant left hepatic arteries arising from left gastric arteries and their clinical importance. *Surgeon* 2020, 18:100–112
2. WAKI Y, KAMIYA S, LI Y, HIKAGE M, TANIZAWA Y, BANDO E ET AL. Preserving a replaced left hepatic artery arising from the left gastric artery during laparoscopic distal gastrectomy for gastric cancer. *World J Surg* 2021, 45:543–553

Corresponding author:

K. Boulas, Department of General Surgery, General Hospital of Drama, 661 00 Drama, Greece  
e-mail: boulaskonstantinos@gmail.com