

## CONTINUING MEDICAL EDUCATION ΣΥΝΕΧΙΖΟΜΕΝΗ ΙΑΤΡΙΚΗ ΕΚΠΑΙΔΕΥΣΗ

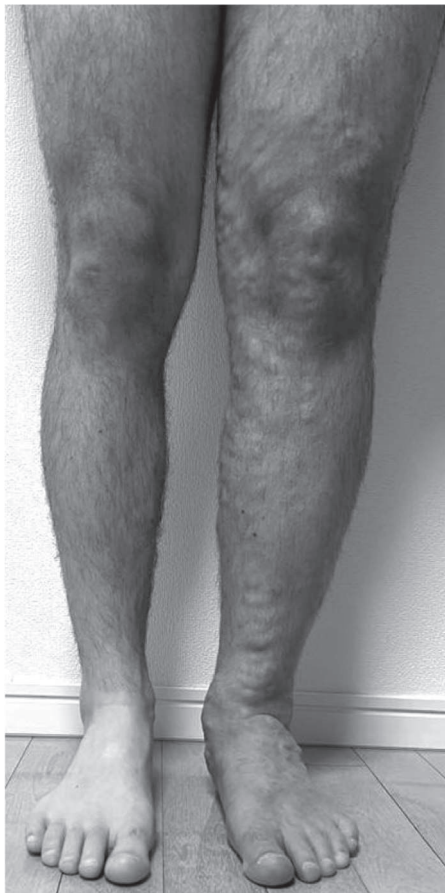---

### Vascular Diseases Quiz – Case 63

A 42-year-old male presents with left leg edema. He describes feeling his left leg heavy and difficult to move. The patient is otherwise fit and well with no significant past medical history. The edema started a couple of years ago and gradually deteriorated. The circumference of the affected extremity is increased two-fold compared to the contralateral leg (fig. 1). What is the differential diagnosis and how should you proceed with the diagnostic workup?

#### Comment

*Differential diagnosis of chronic edema of the lower extremities includes lymphedema, myxedema, renal insufficiency, heart insuf-*



**Figure 1.** Edematous left lower extremity.

ARCHIVES OF HELLENIC MEDICINE 2022, 39(6):862–863  
ΑΡΧΕΙΑ ΕΛΛΗΝΙΚΗΣ ΙΑΤΡΙΚΗΣ 2022, 39(6):862–863

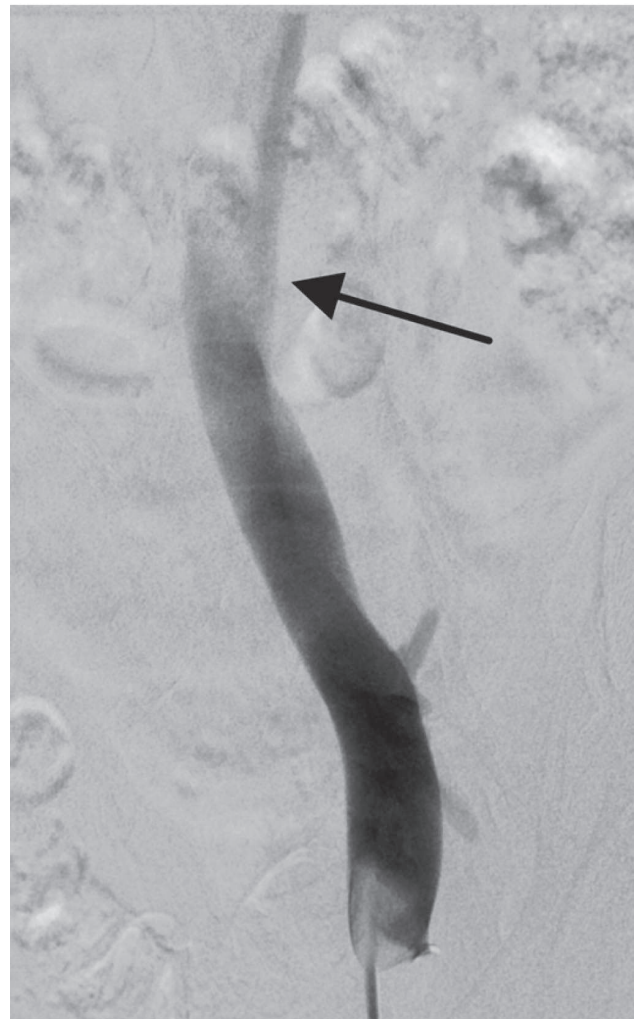
---

**N. Patelis**

---

*Third Department of Vascular Surgery,  
Athens Heart Center, Athens Medical  
Center, Marousi, Attica, Greece*

*ficiency, vein pathology (vein compression, post-thrombotic stenosis or occlusion, chronic vein insufficiency). In this case, myxedema, heart and renal pathology are excluded as they should affect both lower extremities equally.*



**Figure 2.** Phlebography of the left common iliac vein. Arrow indicates the suspected compressed segment, later confirmed by an intravascular ultrasound scan (IVUS).

A colour duplex scan should be performed to examine the superficial and the deep vein systems. In this patient, both vein systems are patent but with significant reflux. As there is no history of known deep vein thrombosis, a pelvic computed tomography angiography (CTA) was performed to exclude compression of the left common iliac vein (CIV). Despite that there was no characteristic compression of the left CIV, its lumen appeared narrowed compared to the contralateral CIV. A phlebography and an intravascular ultrasound scan (IVUS) confirmed the compression of the left CIV by the right common iliac artery – May-Thurner syndrome (fig. 2). Vein stenting was performed relieving the edema of the left leg. Compression stockings further improved the function of the extremity and eased the symptoms.

## References

1. MOOSAVI J, SADEGHIPOUR P, MOHEBBI B, REZAEI-KALANTARI K, KHALILIPUR E. A rare case of left inferior vena cava presenting with May-Thurner syndrome. *CVIR Endovasc* 2022, 5:31
2. KIM JH, LEE SK, KIM EH, KIM JY. Acute left iliofemoral vein thrombosis: Comparison between simple and bony May-Thurner syndrome in CT venography. *Vascular* 2022, 28:17085381221111010

Corresponding author:

N. Patelis, Department of Vascular Surgery, Athens Heart Center, Athens Medical Center, 151 25 Marousi, Attica, Greece  
e-mail: patelisin@gmail.com