

CLINICAL CASE ΚΛΙΝΙΚΗ ΠΕΡΙΠΤΩΣΗ

A historical appraisal of lupus nephritis

The understanding of lupus nephritis over the past five decades has been phenomenal. Kidney biopsy is now the gold standard for its diagnosis, evaluation and management. However, lupus nephritis is a medical entity of recent vintage. The term “lupus”, derived from Latin for wolf, was introduced in the Middle Ages to label nondescript erosive skin lesions resembling wolf bites. The specific dermatologic features of lupus were characterised as a non-erosive “erythematous” butterfly rash in 1828 and termed “lupus erythematosus” in 1850. Their association with systemic manifestations was described in 1872 as “disseminated lupus erythematosus”. The generic term “nephritis” was first used to describe the renal lesions of systemic lupus erythematosus (SLE) in 1902. Although albuminuria and abnormal urine sediment were often noted in SLE patients, initial studies of their renal changes was limited to post-mortem studies. Clarification of the lesions of lupus nephritis came only after the introduction of kidney biopsies in the 1950s and was refined thereafter by immunofluorescent and electron microscopic studies. Subsequent studies of lupus nephritis paralleled the emerging discipline of immunology that identified autoimmunity as the cause of SLE. The varied lesions observed in lupus nephritis were classified by glomerular changes in 1975 and refined in 2003.

1. INTRODUCTION

Lupus nephritis, a serious manifestation of systemic lupus erythematosus (SLE), is an entity of recent vintage. SLE is a disease that can be difficult to diagnose because of the variable nature of its clinical manifestations, its recurrent episodes of recovery and relapse, and the numerous antigens and antibodies incriminated in its pathogenesis, especially since the failure to find them does not rule out the diagnosis of SLE while their presence is not invariably associated with clinical evidence of disease.¹ Kidney biopsy has become an essential component of the diagnosis, course, outcome and management of renal involvement in SLE.²⁻⁵ The history of lupus nephritis can best be gleaned from an appraisal of how an ancient skin disease came to be identified as a systemic disease of varied manifestations, including that of kidney disease, which is now recognised as the most serious of its many complications.

2. LUPUS

2.1. An ancient skin disease

The term *lupus*, derived from the Latin for wolf, was

introduced to label a vague group of ulcerative or necrotic skin lesions that resembled wolf bites.⁶⁻¹¹ As a lesion of external manifestation, it was readily observed and attracted medical attention early in the history of medicine. It is generally accepted now that the disease made its entry into the parlance of medicine in the fourth century BC, in the Hippocratic Corpus as “*herpes esthiomenos*”, designating an erosive or corroding lesion that gnaws at the skin (*esthiomenos*) and creeps like a snake (*herpes derived from the Greek “herpein” for the verb “to creep”; a compound word from the Greek verb esthio meaning “to eat” and herpein...*).⁶⁻¹² In earlier Cnidian medicine it had been referred to as “*serpiginous ulcers*”. The appearance and usually the spread of the lesion have continued to determine its nomenclature. Thus, it was likened to the crawling of ants by the Roman encyclopaedist Celsus (c. 25 BC–c. 50 AD) who dubbed it “*formica corrosiva*” and “*formica ambulativa*”, terms that entered Arabic medicine as a lesion that spreads like ants, “*namleh*”.⁶⁻¹¹ The preceding animal iconography of the skin lesions is likely what led in the Middle Ages to noting their resemblance to the bites of a hungry wolf that gnaws at the skin of its victims, hence their being termed *lupus*. This new nomenclature is likely due to the fact that it was in the Middle Ages that changes in landscape to ac-

ARCHIVES OF HELLENIC MEDICINE 2020, 37(Suppl 2):187–191
ΑΡΧΕΙΑ ΕΛΛΗΝΙΚΗΣ ΙΑΤΡΙΚΗΣ 2020, 37(Συμπλ 2):187–191

G. Eknoyan,¹
M. Airy²

¹Department of Medicine, Baylor College of Medicine, Houston, Texas

²Baylor College of Medicine, Houston, Texas, USA

Μια ιστορική ανασκόπηση
της νεφρίτιδας του λύκου

Περίληψη στο τέλος του άρθρου

Key words

Collagen diseases
Lupus erythematosus
Lupus nephritis
Nephritis
Systemic lupus erythematosus

commodate the expanding agricultural undertakings of feudal estates led to deforestation, changing the habitat of the native wolves who as predatory animals attacked the now adjoining farmers and their herds. It is also then that stories related to the “big bad wolf” began to appear in the literature of the period.¹³

Use of the term “*lupus*” for the Hippocratic herpetic lesions has been attributed to the Salertinian surgeon Rogerius dei Frugardi (c. 1140–c. 1195). Actually, *lupus* is mentioned in an earlier 10th century account of the magical healing of the skin disease of Heraclius (d. 971), bishop of Liège, by the intercession of St. Martin of Tours (d. 397) who appeared to him in a dream and miraculously saved the bishop from “*the point of death by the disease called lupus*”. The failure of the skin lesions to respond to treatment and their aggravation by the irritant agents used then led to their being also termed “*noli me tangere*”, the Latin version of the Biblical “touch me not” to indicate that they are best left alone rather than manipulated.^{6–11} Under any circumstance, the skin lesion we now term lupus erythematosus may not have been called lupus throughout most of past medical history as the term was then applied to a varied cluster of nondescript erosive skin lesions.¹⁴

Some elucidation of the vague entity that was lupus began to surface in the 19th century, when medicine transitioned from its roots as a descriptive discipline into one based on explanatory and investigative studies (fig. 1). It was during this epochal transformative period that medical specialties began to emerge including that of dermatology whose studies were clarified by the publication of atlases of life-like coloured illustrations of skin lesions that allowed for the more accurate comparative study of specific skin diseases than that of their past rather ambiguous verbal description. This step forward was enhanced by improved histological techniques of examining skin biopsies that led to the use of morphological criteria in characterising skin lesions in general and of lupus in particular. It was then that the specific dermatologic features of lupus rather than being corrosive were characterised as a warm reddish rash that spread centrifugally (*érythème centrifuge*) in 1828 by the French dermatologist Laurent T. Biett (1781–1840) and dubbed “*lupus érythémateux*” (lupus erythematosus) in 1850 by his student Pierre Alphonse Cazenave (1795–1877).^{6–11} This was the first qualification of the skin lesion of lupus by its colour as an erythematous rash that is circular and spreads centrifugally, and its differentiation from the host

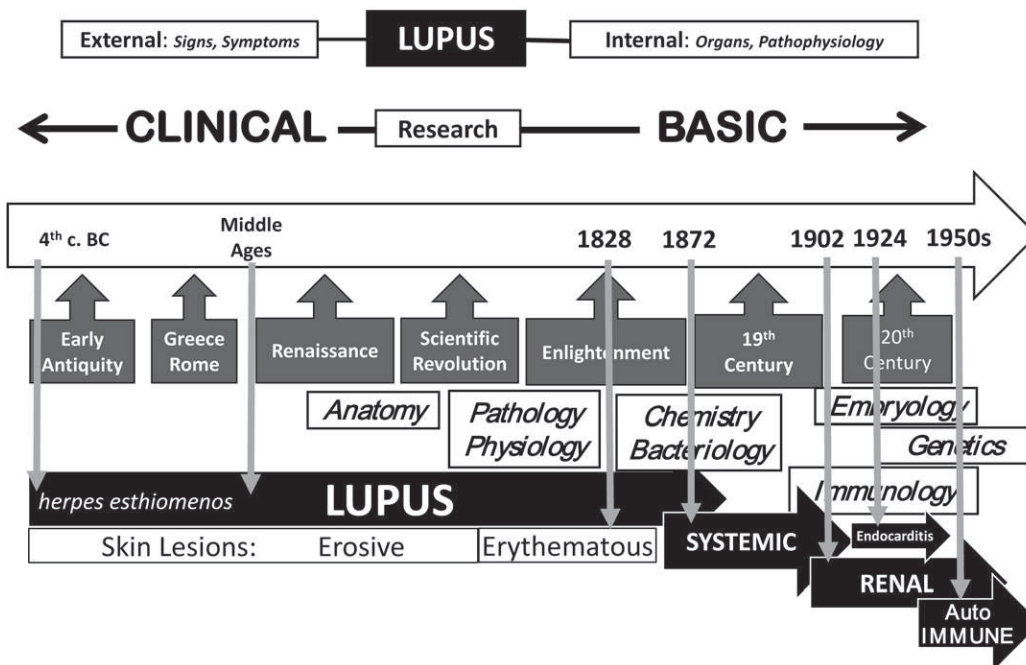


Figure 1. A timeline of the evolution of the disease that came to be called lupus and the emergence of lupus nephritis as a kidney disease. The upper part of the figure shows the conceptual evolution of diseases from a descriptive clinical phase of external findings to that of an investigative basic research phase of internal organ involvement and pathophysiology. The long arrow in the centre of the figure represents a time line of the classic historical periods shown in the black boxed arrows (with white lettering) below the long arrow. Immediately below those, shown in white rectangular boxes (with *italic* black lettering) are the corresponding temporal emergences of the basic sciences. The bottom arrows show the timeline of the evolution of lupus from its recognition in antiquity as an erosive skin lesion (*herpes esthiomenos*, *lupus*) to its identification as a systemic disease in 1872, affecting the kidneys in 1902, causing endocarditis in 1924 and its ultimate determination as an autoimmune disease.

of varied erosive skin lesions with which it had been classified theretofore, particularly those of then prevalent skin lesions of tuberculosis known as "*lupus vulgaris*".¹⁵

Of note in this regard and relevant to the kidney is the two-volume illustrated atlas of skin diseases published in 1826–1827 by the French dermatologist, later nephrologist, Pierre Rayer (1793–1867), a contemporary of Bielt and Cazenave in Paris.¹⁶ In his book, published two years before Bielt's report, Rayer classifies lupus as a tubercular lesion.

2.2. A systemic disease

Lupus erythematosus continued to be considered a skin disease until 1872, when the Austrian dermatologist Ferdinand von Hebra (1816–1880) and his son-in-law Moritz Kaposi (1837–1902) reported some of the systemic manifestations of the disease such as arthralgia, fever, weight loss, anaemia, amenorrhoea, lymphadenopathy, and pulmonary inflammation. It is on this basis that Kaposi went on to separate the lesions of lupus erythematosus as limited to the skin only or "*discoïd lupus*" as opposed to the one associated with systemic manifestations or "*lupus disseminates*" (disseminated lupus).^{6–11} To avoid confusion in using the adjective "disseminated", it was proposed to replace it by "systemic" in 1904 by the German dermatologist Josef Jadassohn (1863–1936) (fig. 1).^{11–17} Still, the use of "disseminated lupus" prevailed well into the 1960s, when it was finally replaced the more specific "systemic lupus erythematosus" now in use.

Even after the description of its systemic manifestations, lupus remained in the realm of dermatology until 1924 when the non-bacterial valvular and mural atypical verrucous cardiac lesions of SLE were described by Emmanuel Libman (1872–1946) and Benjamin Sacks (1896–1971), and achieved prominence as the eponymous "*Libman-Sacks endocarditis*".¹⁸ All glomerulonephritis. It was because of the prevailing interest in diseases of the heart at the time that this new cardiac feature more than any of the other reported systemic manifestations of the disease rekindled interest in SLE. It was in the course of studies of cases of Libman-Sacks disease that lupus nephritis was reported then by George Baehr (1887–1978), who had a standing interest in the glomerular lesions of endocarditis.^{19,20}

It was from these studies of Libman-Sachs endocarditis that a distinctive pathologic feature of SLE was identified in the early decades of the 20th century as a mucoid degeneration of the collagen tissue of involved organs that was termed "*fibrinoid necrosis*" by the pathologist Paul Klemperer (1887–1964) and his associates.¹⁹ In their original

1935 report of fibrinoid necrosis in the visceral lesions of 23 cases of SLE studied at post-mortem, all of their 23 cases had albuminuria or an abnormal urine sediment, and 18 of them had glomerular abnormalities on microscopy.²⁰ Also, it was within the concept of fibrinoid degeneration that the descriptive term "*wire loop*" lesion of the kidney was introduced and came to be considered pathognomonic of SLE, being observed in 20% to 60% of autopsied cases.²¹

2.3. A kidney disease

The further study of SLE led to the identification of a rapidly progressive so-called "active" form of the disease that was associated with grave complications and usually a fatal outcome within a period of weeks to five years. It was from the post-mortem studies of these "active" cases that the renal lesions of lupus were first identified. Credit for the early study of the kidney in SLE belongs to a forgotten nephrologist, Norman M. Keith (1885–1976), one of the many generalist pioneers of the 20th century who devoted most of their effort to the study of the kidney in the period that preceded the emergence of nephrology as a specialty in 1961.²² Notable amongst his publications is one from 1922, describing four cases of SLE with definite renal manifestations (proteinuria, haematuria, casts, azotemia, elevated creatinine) and of glomerular proliferative lesions of the kidney in the one case that was studied at post-mortem.

Early attempts at describing lupus nephritis were all based on post-mortem observations. It was the advent of percutaneous needle biopsy of the kidney that would set the next stage for the emergence of the term "lupus nephritis".²³ In fact, one of the first applications of percutaneous kidney biopsies was to the study of SLE leading to a milestone article published in 1957 by the Chicago team of Robert Kark (1911–2002), Conrad L. Pirani (1914–2005), Robert Muehrcke (1921–2003) and Victor E. Pollak.²⁴ Based on kidney biopsies from 33 patients they demonstrated for the first time the different glomerular changes of lupus nephritis based principally on light microscopy. These initial studies enriched by immunofluorescent and electron microscopic studies on 87 patients was reported in yet another landmark paper on lupus nephritis in 1964 by the same authors.²⁵

On the basis of these and subsequent studies, the varied renal lesions of SLE came to be classified as normal, glomerulitis, active glomerulonephritis and membranous glomerulonephritis. At the time, the mesangium was still not identified as a distinct structural component of the glomerulus, and glomerulitis referred to what would later become the mesangial lesions of SLE.²⁶ A first attempt to

classify the renal lesions of SLE was by the World Health Organization (WHO) that was published in 1975. With increased use of immunopathologic and electronmicroscopic studies attempts at refining the classification of lupus nephritis were formalised under the joint auspices of the International Society of Nephrology (ISN) and the Renal Pathology Society (RPS) in 2003. The six categories described are based primarily on the glomerular changes, but also include as subcategories those that affect the vasculature, tubules and interstitium.^{27,28}

2.4. An autoimmune disease

Throughout the period when its clinical features were being identified SLE went on as a disease of unknown etiology.²⁹ The solution to its pathogenesis would come from the study of infectious diseases that solved the mystery of contagious diseases and launched the study of bacteria in the 1860s. The toxins produced by bacteria and their specific antitoxins produced by the defensive system of the body in time became the antigens and antibodies of immunology. It was the study of how the body protects itself against the threat of foreign pathogens that provided a better understanding of how the immune system senses, attacks and deals with these invaders without destroying the body's own cells and tissues.^{29,30}

It was within these evolving early notions of immunology that a pathognomonic feature of SLE emerged from the observation of haematoxylin bodies in the cardiac lesions of Libman-Sacks disease in 1932. These were the damaged nucleoproteins of injured cells which when ingested by

leukocytes became the LE cells first identified in 1948 by the haematologist Malcolm Hargraves (1903–1982) and his associates.^{31,32} The discovery of LE cells resulted in the more accurate differentiation of SLE from other connective tissue disorders. Soon afterwards the serologic factor inducing the LE cell was identified as a gamma globulin in 1958 and termed antinuclear antibody (ANA).³² The almost simultaneous availability of antibiotics, adrenocorticotropic hormone and adrenal corticosteroids to control the clinical manifestations of SLE led to improved survival of SLE patients and allowed for the long-term studies of the evolution of lupus nephritis by repeated kidney biopsies.

As originally defined, the immune system was conceived as a defender of the self from exterior attacks. When the possibility that the immune system can malfunction and unleash its destructive forces upon the body began to be recognised in the 1950s it was considered anathema to the wisdom of the body as a well-ordered machine in which the immune system was the protector of the self. This betrayal, dubbed “*horror autointoxicus*” by Paul Ehrlich (1854–1915), was ultimately shown to be the inability of the body to maintain immune tolerance against its own cells and identified as the cause of autoimmune diseases.^{33,34} By the 1960s autoimmunity as the mechanism underlying a variety of chronic ailments was established, with SLE as the prototypic autoimmune disease in the lead (fig. 1). That was just about the time that nephrology was flourishing as a discipline and autoimmunity came to be identified as the cause of a growing number of renal diseases and in fact immunology itself was enriched by studies of kidney disease and renal transplantation.

ΠΕΡΙΛΗΨΗ

Μια ιστορική ανασκόπηση της νεφρίτιδας του λύκου

G. EKNOYAN,¹ M. AIRY²

¹Department of Medicine, Baylor College of Medicine, Houston, Texas, ²Baylor College of Medicine, Houston, Texas, ΗΠΑ

Αρχεία Ελληνικής Ιατρικής 2020, 37(Συμπλ 2):187–191

Η κατανόηση της νεφρίτιδας του λύκου τις τελευταίες πέντε δεκαετίες ήταν εκπληκτική. Η βιοψία των νεφρών είναι πλέον το χρυσό πρότυπο για τη διάγνωση, την αξιολόγηση και τη διαχείρισή της. Ωστόσο, η νεφρίτιδα του λύκου είναι πρόσφατη ιατρική νόσος. Ο όρος «λύκος», που προέρχεται από τη λατινική λέξη για τον λύκο, εισήχθη στον Μεσαίωνα για να επισημάνει κοινές διαβρωτικές αλλοιώσεις του δέρματος που ομοιάζουν με δαγκώματα λύκου. Τα συγκεκριμένα δερματολογικά χαρακτηριστικά του λύκου χαρακτηρίστηκαν ως μη διαβρωτικό «ερυθηματώδες» εξάνθημα πεταλούδας το 1828 και ονομάστηκε «ερυθηματώδης λύκος» το 1850. Η συσχέτισή τους με συστηματικές εκδηλώσεις περιγράφηκε το 1872 ως «διάχυτος ερυθματώδης λύκος». Ο γενικός όρος «νεφρίτιδα» χρησιμοποιήθηκε αρχικά για να περιγράψει τις νεφρικές αλλοιώσεις του συστηματικού ερυθματώδους λύκου (SLE) το 1902. Παρ' όλο που παρατηρήθηκε συχνά λευκωματουρία και μη φυσιολογικά ιζήματα ούρων σε ασθενείς με SLE, οι αρχικές μελέτες των

νεφρικών τους αλλαγών περιορίστηκαν σε μεταθανάτιες μελέτες. Η διευκρίνιση των αλλοιώσεων της νεφρίτιδας του λύκου ήρθε μόνο μετά την εισαγωγή βιοψιών νεφρού στη δεκαετία του 1950 και στη συνέχεια βελτιώθηκε με ανοσοφθορισμούς και με ηλεκτρονικές μικροσκοπικές μελέτες. Οι μεταγενέστερες μελέτες της νεφρίτιδας του λύκου κινούνταν παράλληλα με την αναδυόμενη επιστήμη της Ανοσολογίας που αναγνώρισε την αυτοανοσία ως την αιτία του SLE. Οι ποικίλες αλλοιώσεις που παρατηρήθηκαν στη νεφρίτιδα του λύκου ταξινομήθηκαν με πειραματικές αλλαγές το 1975 και βελτιστοποιήθηκαν το 2003.

Λέξεις ευρητηρίου: Ερυθματώδης λύκος, Νεφρίτιδα, Νεφρίτιδα του λύκου, Παθήσεις κολλαγόνου, Συστηματικός ερυθματώδης λύκος

References

1. YU C, GERSHWIN ME, CHANG C. Diagnostic criteria for systemic lupus erythematosus: A critical review. *J Autoimmun* 2014, 48–49:10–13
2. ALMAANI S, MEARA A, ROVIN BH. Update on lupus nephritis. *Clin J Am Soc Nephrol* 2017, 12:825–835
3. SEXTON DJ, REULE S, SOLID C, CHEN SC, COLLINS AJ, FOLEY RN. ESRD from lupus nephritis in the United States, 1995–2010. *Clin J Am Soc Nephrol* 2015, 10:251–259
4. TEKTONIDOU MG, DASGUPTA A, WARD MM. Risk of end-stage renal disease in patients with lupus nephritis; 1971–2015. *Arthritis Rheumatol* 2016, 68:1432–1441
5. HANLY JG, SU L, UROWITZ MB, ROMERO-DIAZ J, GORDON C, BAE SC ET AL. A longitudinal analysis of outcomes of lupus nephritis in an international inception cohort using a multistate model approach. *Arthritis Rheumatol* 2016, 68:1932–1944
6. JARCHO S. Notes on the early modern history of lupus erythematosus. *J Mt Sinai Hosp N Y* 1957, 24:939–944
7. POTTER B. The history of the disease called lupus. *J Hist Med Allied Sci* 1993, 48:80–90
8. SMITH CD, CYR M. The history of lupus erythematosus. From Hippocrates to Osler. *Rheum Dis Clin North Am* 1988, 14:1–14
9. HOLUBAR K. History of lupus erythematosus. *Acta Dermatovenol Alp Pannonica Adriat* 2006, 15:191–194
10. MALLAVARAPU RK, GRIMSLEY EW. The history of lupus erythematosus. *South Med J* 2007, 100:896–898
11. NORMAN RA. The history of lupus erythematosus and discoid lupus: From Hippocrates to the present. *Lupus Open Access* 2016, 1:1:1000102
12. BESWICK TS. The origin and the use of the word herpes. *Med Hist* 1962, 6:214–232
13. MORICEAU J. *The wolf threat in France from the Middle Ages to the twentieth century*. HAL archives-ouvertes, 2014. Available at: <https://hal.archives-ouvertes.fr/hal-01011915>
14. HUTCHINSON J. Harveian lectures on lupus. *Br Med J* 1888, 1:6–10, 58–63, 113–118
15. RUSSELL B. The history of lupus vulgaris: Its recognition, nature, treatment and prevention. *Proc R Soc Med* 1955, 48:127–132
16. RICHET G. From Bright's disease to modern nephrology: Pierre Rayer's innovative method of clinical investigation. *Kidney Int* 1991, 39:787–792
17. LIBMAN E, SACKS B. A hitherto undescribed form of valvular and mural endocarditis. *Arch Intern Med (Chic)* 1924, 33:701–737
18. KLEMPERER P, POLLACK AD, BAEHR G. Pathology of disseminated lupus erythematosus. *Arch Pathol* 1941, 32:569–631
19. BAEHR G, KLEMPERER P, SCHIFFRIN A. A diffuse disease of peripheral circulation (usually associated with lupus erythematosus and endocarditis). *Trans Assoc Am Physicians* 1935, 50:139–155
20. KLEMPERER P. The concept of collagen diseases. *Am J Pathol* 1950, 26:505–519
21. KEITH NM, ROWNTREE LG. A study of the renal complications of disseminated lupus erythematosus: Report of four cases. *Trans Assoc Am Physicians* 1922, 37:487–502
22. CAMERON JS, HICKS J. The introduction of renal biopsy into nephrology from 1901 to 1961: A paradigm of the framing of nephrology by technology. *Am J Nephrol* 1997, 17:347–358
23. MUEHRCKE RC, KARK RM, PIRANI CL, POLLAK VE. Lupus nephritis: A clinical and pathologic study based on renal biopsies. *Medicine (Baltimore)* 1957, 36:1–145
24. POLLAK VE, PIRANI CL, SCHWARTZ FD. The natural history of the renal manifestations of systemic lupus erythematosus. *J Lab Clin Med* 1964, 63:537–550
25. MICHAEL AF, KEANE WF, RAJJ L, VERNIER RL, MAUER SM. The glomerular mesangium. *Kidney Int* 1980, 17:141–154
26. GUPTA RK. Current classification of lupus nephritis. *J Indian Rheumatol Assoc* 2005, 13:156–161
27. WEENING JJ, D'AGATIVD, SCHWARTZ MM, SESHAN SV, ALPERS CE, APPEL GB ET AL. Classification of glomerulonephritis in systemic lupus erythematosus revisited. *Kidney Int* 2004, 65:521–530
28. ANDERSON W, MACKAY IR. *Intolerant bodies. A short history of autoimmunity*. Johns Hopkins University Press, Baltimore, MD, 2014
29. TRAVIS J. Origins. On the origin of the immune system. *Science* 2009, 324:580–582
30. HARGRAVES MM, RICHMOND H, MORTON R. Presentation of two bone marrow elements; the tart cell and the L.E. cell. *Proc Staff Meet Mayo Clin* 1948, 23:25–28
31. HOLMAN HR. The L.E. cell phenomenon. *Annu Rev Med* 1960, 11:231–242
32. JENNETTE JC, FALK RJ. The rise and fall of horror autotoxicus and forbidden clones. *Kidney Int* 2010, 78:533–535
33. CHANG C. Autoimmunity: From black water fever to regulatory function. *J Autoimmun* 2014, 48–49:1–9
34. HEATH V, MASON D, RAMIREZ F, SEDDON B. Homeostatic mechanisms in the control of autoimmunity. *Semin Immunol* 1997, 9:375–380

Corresponding author:

G. Eknayan, Department of Medicine, Baylor College of Medicine, Houston, TX 77030, USA
e-mail: geknayan@bcm.edu