

CONTINUING MEDICAL EDUCATION ΣΥΝΕΧΙΖΟΜΕΝΗ ΙΑΤΡΙΚΗ ΕΚΠΑΙΔΕΥΣΗ

Medical Imaging Quiz – Case 52

A 42-year-old man presented to the emergency department due to fever for 48 hours and severe, rapidly worsening dyspnea. He referred being a heavy smoker for 25 years with free medical history. At initial physical examination, body temperature was 39.1 °C, blood pressure was 130/95 mmHg, pulse was 146 beats per minute and respiratory rate was 20 breaths per minute. Lung auscultation revealed reduced bibasilar inspiratory crackles and rhonchi on forced exhalation. Blood tests revealed mild elevation of white blood count. Chest x-ray showed diffuse parenchymal opacities mainly over the left lung (fig. 1a). Chest computed tomography (CT) showed multiple solid like infiltrations at the left lung (fig. 1b). Our patient underwent bronchoscopy and pulmonary lavage confirmed the diagnosis.

Comments

Acute eosinophilic pneumonia (AEP) is a type of eosinophilic lung disease usually manifests with acute onset fever, severe dyspnea and hypoxia for <5 days with rapid progression and shows rapid improvement when treated with steroids and usually no relapse after treatment. Pulmonary lavage reveals >25% eosinophils. The etiology of AEP is unknown, most cases are idiopathic. It has been suggested that it may represent acute hypersensitivity to an inhaled antigen. It can occur at any age, even in previously healthy children,

though most patients are between 20 and 40 years of age. Men are affected approximately twice as frequently as women.

Patients present with an acute illness of less than seven days. Nonproductive cough (95%), dyspnea (92%), and fever (88%) are present in almost every patient. Physical examination shows fever (often high) and tachypnea. Hypoxemic respiratory insufficiency is frequently identified at presentation and often requires mechanical ventilation. Patients generally present with an initial neutrophilic leukocytosis. In most cases, the eosinophil fraction is not elevated initially, but may become markedly elevated during the subsequent course. The erythrocyte sedimentation rate and C-reactive protein are elevated, and the IgE level has been high in a majority of the patients in whom it was measured.

Acute eosinophilic pneumonia is typically suspected in a patient with progressive dyspnea less than a month in duration and a chest radiograph showing diffuse parenchymal opacities. Among the first steps in the evaluation is to ask the patient about medication usage, particularly any drugs associated with pulmonary eosinophilia,

ARCHIVES OF HELLENIC MEDICINE 2018, 35(6):852–853
ΑΡΧΕΙΑ ΕΛΛΗΝΙΚΗΣ ΙΑΤΡΙΚΗΣ 2018, 35(6):852–853

**E. Botsa,
I. Thanou,
A. Koundouraki,
L. Thanos**

*Department of Interventional Radiology
and Diagnostic Imaging, "Sotiria"
General Hospital of Chest Diseases,
Athens, Greece*

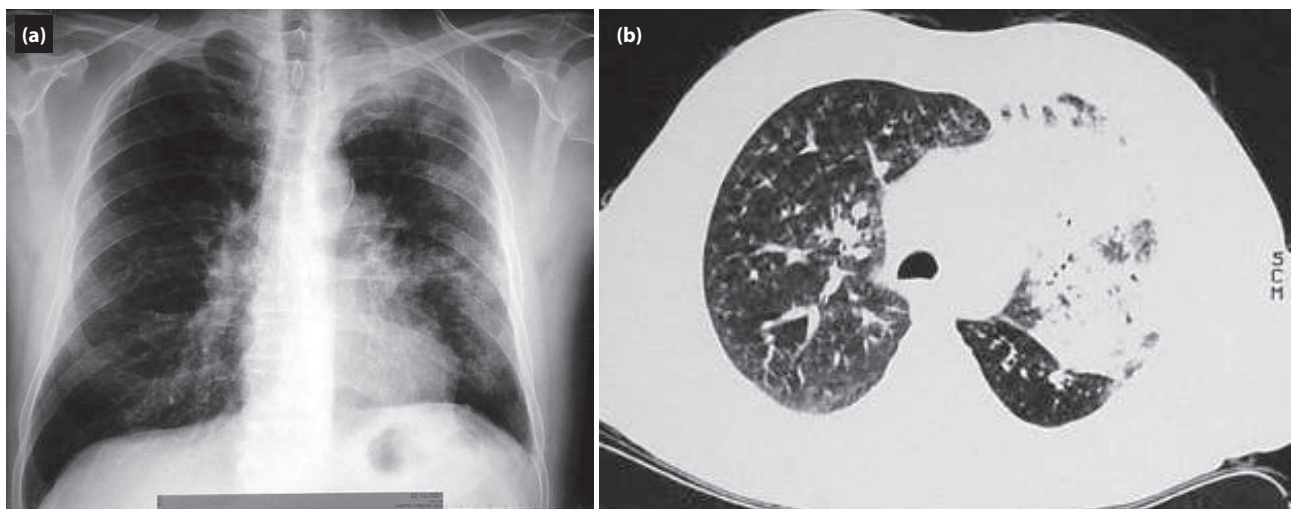


Figure 1. (a) Chest x-ray reveal multiple diffuse opacities mainly in the left lung. **(b)** Chest computed tomography (CT) scan reveal bilateral diffuse mixed ground glass and reticular opacities, and solid like consolidation of the left lung.

previous irradiation of the chest, or travel or residence in an area with an increased likelihood of exposure to endemic parasites or fungi. No laboratory studies are specific for AEP. However, in the evaluation of patients with dyspnea, cough, fever, and radiographic pulmonary opacities, the usual laboratory tests include a complete blood count and differential, blood urea nitrogen, creatinine, hepatic function tests, urinalysis, and blood cultures. As noted above, patients do not typically have peripheral blood eosinophilia at the time of presentation.

At the onset of AEP, the chest radiograph may show only subtle reticular or ground glass opacities. As the disease progresses, bilateral diffuse mixed ground glass and reticular opacities develop. CT features include bilateral ground-glass areas, interlobular septal thickening, pleural effusions (approximately 80%), thickening of bronchovascular bundles (approximately 60%), air-space consolidation (approximately 50%) and ill-defined centrilobular nodules (approximately 30%). The distribution of opacities in AEP is diffuse. Small pleural effusions are common (noted in up to 70 percent of patients) and are frequently bilateral. The high-resolution computed tomography (HRCT) is always abnormal in patients with AEP and is characterized by bilateral, random, and patchy ground-glass or reticular opacities.

The diagnosis of acute eosinophilic pneumonia is typically based upon clinical criteria that include bronchoalveolar lavage (BAL) eosinophilia with exclusion of known causes of pulmonary eosinophilia. Lung biopsy is rarely necessary.

It is diagnosed when the following combination, clinical and radiographic findings, occur: Febrile illness of less than five days' duration, hypoxemia, diffuse alveolar or mixed alveolar-interstitial opacities on chest radiography, BAL fluid consisting of >25% eosinophils, absence of parasitic, fungal or other infection, prompt and complete response to corticosteroids and no relapse after discontinuation of corticosteroids.

For the majority of patients with AEP, the recommended treatment is systemic glucocorticoids after exclusion of infection due

to the severity and progressive nature of respiratory impairment and the dramatic response to glucocorticoids. The optimal dose of glucocorticoids is not known, but a reasonable course is to select the dose based upon the severity of respiratory impairment.

References

1. JANZ DR, O'NEAL HR Jr, ELY EW. Acute eosinophilic pneumonia: A case report and review of the literature. *Crit Care Med* 2009, 37:1470– 1474
2. CHUNG MK, LEE SJ, KIM MY, LEE JH, CHANG JH, SIM SS ET AL. Acute eosinophilic pneumonia following secondhand cigarette smoke exposure. *Tuberc Respir Dis (Seoul)* 2014, 76:188– 191
3. KING MA, POPE-HARMAN AL, ALLEN JN, CHRISTOFORIDIS GA, CHRISTOFORIDIS AJ. Acute eosinophilic pneumonia: Radiologic and clinical features. *Radiology* 1997, 203:715– 719
4. JOHKOH T, MÜLLER NL, AKIRA M, ICHIKADO K, SUGA M, ANDO M ET AL. Eosinophilic lung diseases: Diagnostic accuracy of thin-section CT in 111 patients. *Radiology* 2000, 216:773– 780
5. DAIMON T, JOHKOH T, SUMIKAWA H, HONDA O, FUJIMOTO K, KOGA T ET AL. Acute eosinophilic pneumonia: Thin-section CT findings in 29 patients. *Eur J Radiol* 2008, 65:462– 467
6. JEONG YJ, KIM KI, SEO IJ, LEE CH, LEE KN, KIM KN ET AL. Eosinophilic lung diseases: A clinical, radiologic, and pathologic overview. *Radiographics* 2007, 27:617– 637
7. SHORR AF, SCOVILLE SL, CERSOVSKY SB, SHANKS GD, OCKENHOUSE CF, SMOAK BL ET AL. Acute eosinophilic pneumonia among US military personnel deployed in or near Iraq. *JAMA* 2004, 292:2997–3005

Corresponding author:

L. Thanos, Department of Computed Tomography, "Sotiria" General Hospital of Chest Diseases, 152 Mesogeion Ave., 115 27 Athens, Greece
e-mail: loutharad@yahoo.com