

CONTINUING MEDICAL EDUCATION ΣΥΝΕΧΙΖΟΜΕΝΗ ΙΑΤΡΙΚΗ ΕΚΠΑΙΔΕΥΣΗ

Vascular Diseases Quiz – Case 48

A 55-year-old male with known thrombocytosis under treatment underwent a color duplex scan of the carotid arteries. In the past, this patient had a platelet count of 750,000/ μL that has been now reduced to 510,000/ μL by receiving low dosage aspirin and hydroxyurea. The patient used to be a heavy smoker and has quit 2 years ago. No other significant medical history existed. The ultrasound scan can be seen in figure 1. The diagnosis was free floating thrombus (FFT) in the internal carotid artery (ICA) adherent to an atherosclerotic plaque of the carotid wall. What is the best treatment for this patient?

Comment

Incidence of a carotid FFT is reported to be lower than 0.9%. ICA is the most frequently affected part, followed by common carotid artery (CCA) and the carotid bifurcation. This pathology is more prevalent in males (2:1) and of younger age compared to the patients affected by carotid atherosclerosis. The etiology of FFT includes cardioembolism, other embolism, dissection, complicated

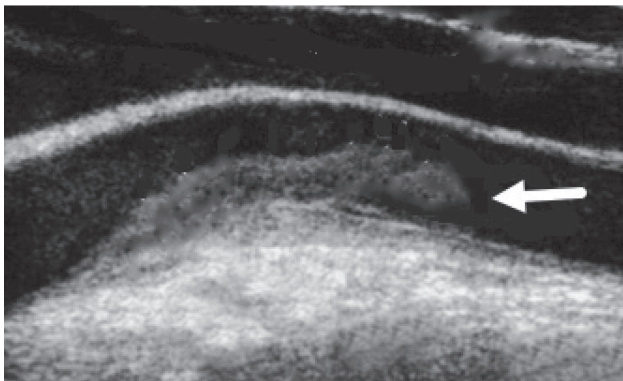


Figure 1. Ultrasound scan of the internal carotid artery. Arrow indicates the free-floating part of the thrombus.

ARCHIVES OF HELLENIC MEDICINE 2018, 35(4):574
ΑΡΧΕΙΑ ΕΛΛΗΝΙΚΗΣ ΙΑΤΡΙΚΗΣ 2018, 35(4):574

**N. Patelis,
C. Klonaris**

First Department of Surgery, Vascular Unit, "Laiko" General Hospital, Medical School, National and Kapodistrian University of Athens, Athens, Greece

atherosclerotic plaque and hypercoagulable states, e.g. thrombocytosis. The most frequently used diagnostic method is angiography but nowadays duplex ultrasound is becoming more frequently used.

Due to the low incidence of FFT in the carotid arteries, no published or accepted guidelines regarding treatment exist. Conservative treatment (antiplatelet, anticoagulation or both combined) and surgical removal of the thrombus are accepted methods of therapy. Many cases have complete thrombus dissolution achieved by conservative treatment, but existing data are not unanimous. Surgical thrombectomy is recommended in symptomatic cases, as peri-procedural stroke rates can be as high as 30%.

References

1. BHATTI AF, LEON LR Jr, LABROPOULOS N, RUBINAS TL, RODRIGUEZ H, KALMAN PG ET AL. Free-floating thrombus of the carotid artery: Literature review and case reports. *J Vasc Surg* 2007, 45:199–205
2. CHUA HC, LIM T, TEO BC, PHUA Z, ENG J. Free-floating thrombus of the carotid artery detected on carotid ultrasound in patients with cerebral infarcts: A 10-year study. *Ann Acad Med Singapore* 2012, 41:420–424
3. BAJKÓ Z, MAIER S, RUSU S, MOȚĂȚĂIANU A. Acute ischaemic stroke secondary to a mobile thrombus in the common carotid artery – case report. *J Crit Care Med* 2015, 1:68–70

Corresponding author:

C. Klonaris, First Department of Surgery, Vascular Unit, "Laiko" General Hospital, Medical School, National and Kapodistrian University of Athens, 115 27 Athens, Greece
e-mail: chris_klonaris@yahoo.com

Diagnosis: Free-floating carotid thrombus