

CONTINUING MEDICAL EDUCATION ΣΥΝΕΧΙΖΟΜΕΝΗ ΙΑΤΡΙΚΗ ΕΚΠΑΙΔΕΥΣΗ

Surgery Quiz – Case 12

A 32-year-old female patient with a history of chronic idiopathic neutropenia referred to our surgical department with complaints of a painful right groin swelling and high grade fever over the preceding two days. Direct questioning revealed no history of a lump or swelling in the right groin, as well as no history of acute abdomen and intestinal obstruction symptoms. At initial presentation a firm, fixed, very tender, reddish, 4×4.5 cm mass with concurrent cellulitis in the right inguinal region of the abdominal wall above the inguinal ligament at the superficial inguinal ring and a normal femoral triangle without signs of acute abdomen and intestinal obstruction were present on physical examination (fig. 1). Laboratory studies revealed a significant increase in C-reactive protein. Abdominal x-rays revealed no signs of intestinal obstruction. Before proceeding to abdominal and groin ultrasound (US) and computed tomography (CT) assessment, differential diagnosis based solely on clinical findings included: (a) Superficial inguinal lymphadenitis, (b) strangulated inguinal hernia, (c) incarcerated inguinal hernia with right-sided omental torsion, (d) incarcerated Amyand's hernia, (e) acute appendicitis in an incarcerated Amyand's hernia.

Which were the most prominent diagnoses?

Comment

Based on clinical findings, (a) and (e) were the two most prominent diagnoses. Superficial inguinal lymphadenitis and acute appendicitis

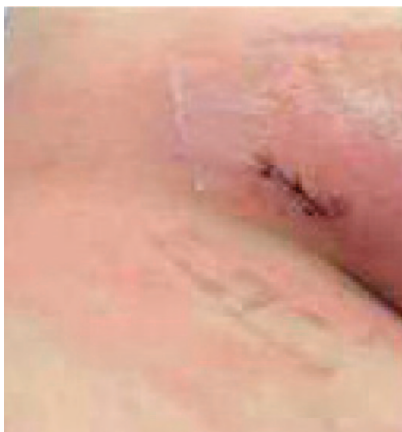

Figure 1. A reddish 4×4.5 cm mass above the right inguinal ligament with concurrent cellulitis was present.

ARCHIVES OF HELLENIC MEDICINE 2018, 35(2):286–287
ΑΡΧΕΙΑ ΕΛΛΗΝΙΚΗΣ ΙΑΤΡΙΚΗΣ 2018, 35(2):286–287

K. Blouhos,
K. Boulas,
K. Iatropoulou,
N. Baretas,
A. Hatzigeorgiadis

Department of General Surgery, General
Hospital of Drama, Drama, Greece

in an incarcerated Amyand's hernia were the only diagnoses that could explain both the presence of a mass with regional signs of inflammation in the right groin, such as the tense, irreducible, very tender swelling with a reddish discoloration of the underlying skin and concurrent cellulitis, along with the absence of symptoms and signs of acute abdomen and intestinal obstruction. Differential diagnosis of the above two entities was easily made by further imaging such as US and CT which revealed radiographic features of inguinal lymphadenitis with 3–4 enlarged nodes clustered in the right superficial inguinal area above the inguinal ligament (fig. 2).

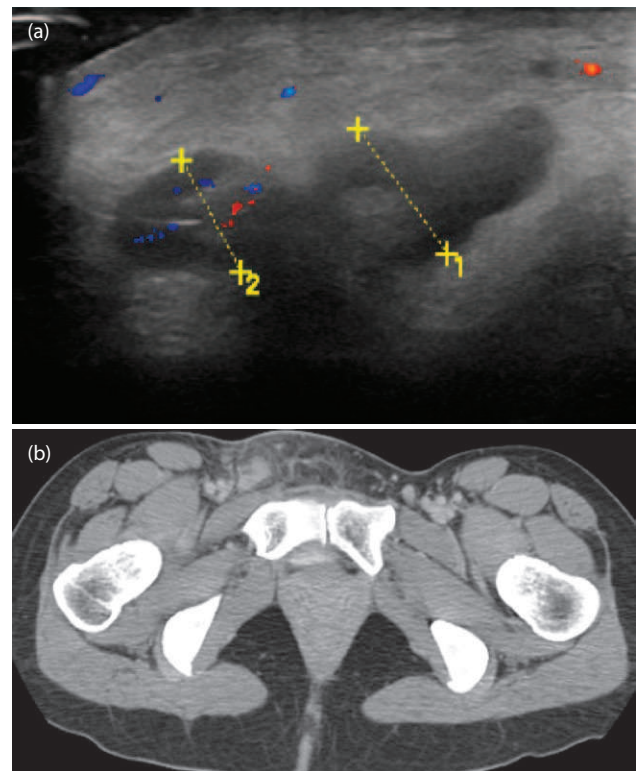


Figure 2. (a) Ultrasonography (US) and (b) computed tomography (CT) showed radiographic features of inguinal lymphadenitis.

Although an unattended strangulated inguinal hernia (b) could explain the signs of regional groin inflammation, this diagnosis was excluded due to the absence of symptoms and signs of intestinal obstruction. An incarcerated inguinal hernia with right-sided omental torsion (c) was excluded due to the absence of symptoms and signs of acute abdomen. The diagnosis of an incarcerated Amyand's hernia (d) with normal vermiform appendix within the hernia sac was excluded as it couldn't explain the presence of signs of regional groin inflammation. Although diagnosis in analogous cases can generally be easily established by further imaging, clinical diagnosis can be challenging and physicians especially in primary care should always look beyond the obvious before making the diagnosis. In the present case, a surgical emergency such as acute appendicitis in an Amyand's hernia should have been excluded before establishing the obvious diagnosis of superficial inguinal lymphadenitis which requires conservative management and

further pathology and hematology consultation.

References

1. ÖBERG S, ANDRESEN K, ROSENBERG J. Etiology of inguinal hernias: A comprehensive review. *Front Surg* 2017, 4:52
2. CONSTANTINE S. Computed tomography appearances of Amyand hernia. *J Comput Assist Tomogr* 2009, 33:359–362
3. MICHALINOS A, MORIS D, VERNADAKIS S. Amyand's hernia: A review. *Am J Surg* 2014, 207:989–995

Corresponding author:

K. Boulas, Department of General Surgery, General Hospital of Drama, Drama, Greece
 e-mail: boulaskonstantinos@gmail.com

Diagnosis: Acute inflammatory mass above the inguinal ligament: Inguinal lymphadenitis or Amyand's hernia with acute appendicitis?