

CONTINUING MEDICAL EDUCATION ΣΥΝΕΧΙΖΟΜΕΝΗ ΙΑΤΡΙΚΗ ΕΚΠΑΙΔΕΥΣΗ

Electrocardiogram Quiz – Case 35

A 56-year-old man presented to the emergency department of our hospital complaining of chest pain of half an hour's duration. The patient's medical history included arterial hypertension under valsartan and diuretic, and dyslipidemia under rosuvastatin. He was hemodynamically stable with normal vital signs. The initial surface electrocardiogram (ECG) is depicted below.

Questions

- What abnormal ECG findings are present?
- Should the patient undergo an immediate coronary angiography, or should the treating team wait for cardiac enzymes assessment?

Comment

Determining an underlying structural heart disease in the presence of a baseline left bundle branch block (LBBB) on surface ECG can be difficult. Ischemic or hypertensive heart disease or cardiomyopathy are plausible considerations. Especially the diagnosis of myocardial infarction in the presence of LBBB can be considerably complicated. The reason is that LBBB alters both the early and the late phases of ventricular depolarization and produces secondary ST-T changes.

Chapman's sign is used to diagnose an acute myocardial infarction in the setting of a LBBB and consists of a notch in the upslope of the R wave in lead I, aVL or V6. This has a low sensitivity, but a specificity of about 90%.

Several other signs have been proposed for the detection of myocardial ischemia and or infarction in the presence of LBBB. A sharp notching of the upstroke of the S wave in the precordial leads is the Cabrera sign. Furthermore, Sgarbossa described some ECG changes seen in those with LBBB and concomitant myocardial infarction and devised a point scoring system, known as the Sgarbossa criteria.

ARCHIVES OF HELLENIC MEDICINE 2017, 34(3):427
ΑΡΧΕΙΑ ΕΛΛΗΝΙΚΗΣ ΙΑΤΡΙΚΗΣ 2017, 34(3):427

E. Petrou,
A. Tsipis,
V. Vartela,
G. Athanassopoulos

Division of Cardiology, "Onassis" Cardiac
Surgery Centre, Athens, Greece

Moreover, among others, the aforementioned signs and criteria can be useful in the electrocardiographic diagnosis of myocardial infarction and ischemia in pacemaker patients. In this group of patients ischemia diagnosis can be challenging due to initial electrical forces obscured by pacing stimuli, presence of ventricular fusion beats (with dual chamber devices), metabolic disorders (especially hyperkalemia), and cardiac memory phenomena.

Our patient underwent coronary angiography and subsequent angioplasty as well as stenting of a dominant circumflex coronary artery.

References

- CHAPMAN MG, PEARCE ML. Electrocardiographic diagnosis of myocardial infarction in the presence of left bundle-branch block. *Circulation* 1957, 16:558–571
- KOCHIADAKIS GE, KALEBOUBAS MD, IGOMENIDIS NE, SKALIDIS EI, SIMANTIRAKIS EN, CHRYSOSTOMAKIS SI ET AL. Electrocardiographic appearance of old myocardial infarction in paced patients. *Pacing Clin Electrophysiol* 2002, 25:1061–1065

Corresponding author:

E.G. Petrou, Division of Cardiology, "Onassis" Cardiac Surgery Centre, 356 Sygrou Ave., 176 74 Kallithea, Greece
e-mail: emmgpetrou@hotmail.com

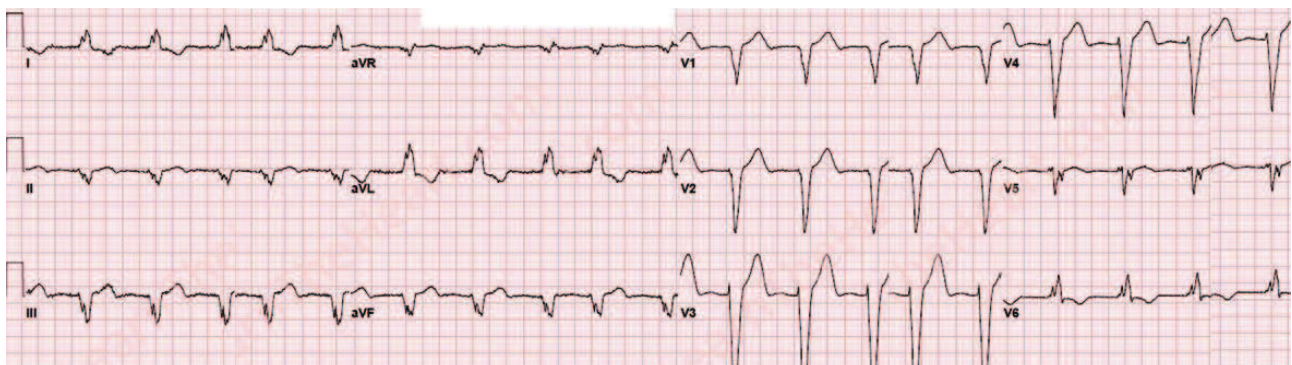


Figure 1

Diagnosis: Chapman's sign