

## CONTINUING MEDICAL EDUCATION ΣΥΝΕΧΙΖΟΜΕΝΗ ΙΑΤΡΙΚΗ ΕΚΠΑΙΔΕΥΣΗ

### Pneumonology Quiz – Case 5

A 78-year-old male patient presented in the emergency department with a gradual deterioration of his general state of health during the preceding month. More specifically, he complained of progressive breathlessness, retrosternal pain radiating throughout his thoracic cavity, dizziness, syncopal episodes and cough, productive of small quantities of pink-tinted phlegm, mainly on exertion. At presentation, the patient appeared severely unwell. He was pale and he scored four in the modified Medical Research Council (mMRC) breathlessness score.

Pulmonary auscultation revealed bilateral coarse crackles throughout the lung fields. Heart sounds were rhythmic, characterized by a loud ejection systolic murmur clearly audible in all auscultation areas and diminished heart sounds in the aortic area. His heart rate was 80 beats per minute and his blood pressure was 100/60 mmHg.

#### Questions

- 1: Please describe the changes on the radiographs.
- 2: Which is the most likely diagnosis?
- 3: Which is your differential diagnosis?

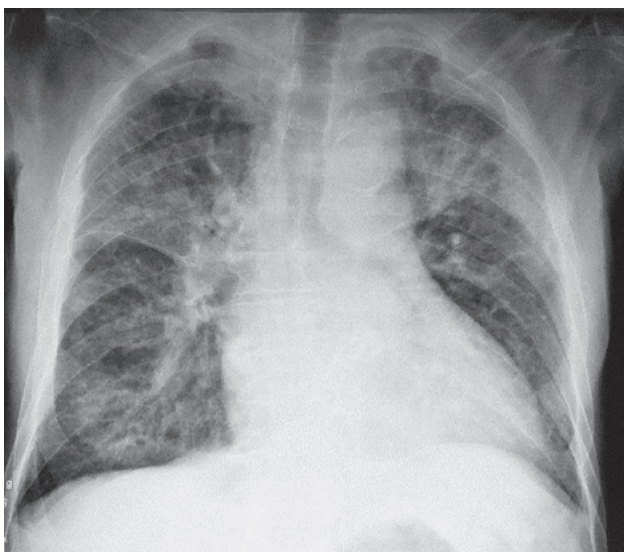


Figure 1

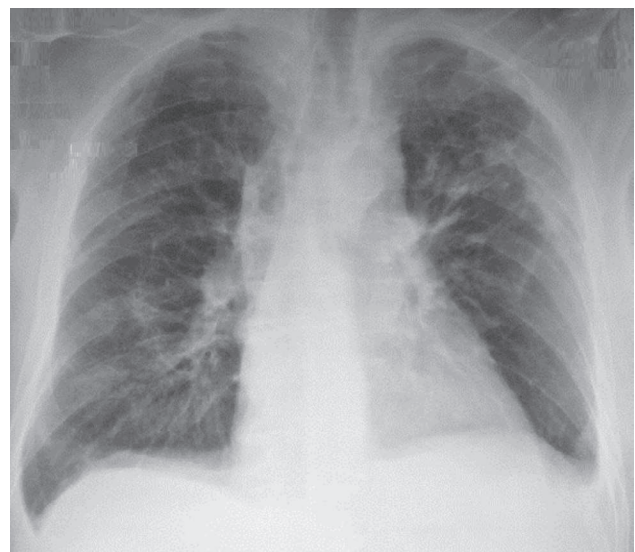


Figure 2

ARCHIVES OF HELLENIC MEDICINE 2017, 34(2):280–281  
ΑΡΧΕΙΑ ΕΛΛΗΝΙΚΗΣ ΙΑΤΡΙΚΗΣ 2017, 34(2):280–281

A. Corlateanu,<sup>1</sup>  
V. Botnaru,<sup>1</sup>  
A.G. Mathioudakis,<sup>2</sup>  
O. Munteanu,<sup>1</sup>  
I. Caraivanova<sup>1</sup>

<sup>1</sup>Department of Respiratory Medicine,  
“Nicolae Testemitanu” State University  
of Medicine and Pharmacy, Chisinau,  
Moldova

<sup>2</sup>Breath Centre of Athens, Athens, Greece

#### Comment – Answers

1. On the first posterior-anterior radiograph (fig. 1), bilateral interstitial infiltrates, more prevalent in the superior and middle areas, are detected. The costodiaphragmatic recesses are obliterated. The hila of the lungs are dense. There is an increase in the caliber of the peripheral vessels. The heart is increased in size. On the second radiograph (fig. 2), there is a significant reduction of the interstitial infiltrates.
2. An echocardiogram has been performed, revealing that the aortic valve is hardened. The transaortic gradient is 62 mmHg. There was a mild dilation of the left atrium (39×68 mm) and of the left ventricle (the transverse diastolic diameter of the left ventricle was 61 mm; the transverse systolic diameter was 44 mm). The ejection fraction was maintained (54%).

*Acute cardiogenic pulmonary edema or acute left ventricular failure, caused by a primary cardiac disease, determining the increment of the hydrostatic pressure in the pulmonary capillaries, followed by massive transudation of plasma into the interstice and the pulmonary alveoli. Aortic stenosis may be one of the causes. Minor stenoses have no cardiovascular consequence. Hemodynamic disturbances occur when the surface of the aortic orifice decreases below 50% and the LV/aortic pressure gradient overcomes 20 mmHg. The disturbances become severe when the surface of the aortic orifice decreases to less than ¼ of the normal size.*

3. *Differential diagnosis includes cardiogenic versus non-cardiogenic pulmonary edema. Characteristics of each entity are described in table 1.*

**References**

1. MATTU A, MARTINEZ JP, KELLY BS. Modern management of cardiogenic pulmonary edema. *Emerg Med Clin North Am* 2005, 23:1105–1125
2. PANG PS, KOMAJDA M, GHEORGHIAD E M. The current and future management of acute heart failure syndromes. *Eur Heart J* 2010, 31:784–793

*Corresponding author:*

Corlateanu, Department of Respiratory Medicine, “Nicolae Testemitanu” State University of Medicine and Pharmacy, 165 Stefan cel Mare street, MD-2004 Chisinau, Republic of Moldova  
 e-mail: alexandru\_corlateanu@yahoo.com

**Table 1.** Differences between cardiogenic and non-cardiogenic pulmonary edema.

	<b>Cardiogenic pulmonary edema</b>	<b>Non-cardiogenic pulmonary edema</b>
Prior cardiac disease	Present	Absent
Third heart sound	Present	Absent
Cardiomegaly	Present	Normal sized heart
Infiltrates	Central distribution	Peripheral distribution
Vascular pedicle	Widening	No widening
PA wedge pressure	Increased PA wedge pressure	Normal or drop
Fluid balance	Positive	Negative

PA: Pulmonary artery