

## CONTINUING MEDICAL EDUCATION ΣΥΝΕΧΙΖΟΜΕΝΗ ΙΑΤΡΙΚΗ ΕΚΠΑΙΔΕΥΣΗ

### Hematology Quiz – Case 52

A 66-year-old lady presented to the outpatient clinic because of progressive normochromic macrocytic anemia of nine months duration, causing fatigue, weakness and malaise. She was treated, before her admission, with IM vitamin B<sub>12</sub> and *per os* folic acid administration, and after a slight first increase, the hemoglobin decreased again to 8.0 g/dL. The diagnosis was refractory macrocytic anemia and the patient needed occasional blood transfusions. Her past medical history included vagotomy 15 years ago, and tuberculosis in childhood, without a history to toxic agents exposure. Her mother died of breast cancer and her father of acute myeloid leukemia.

Physical examination on admission revealed pallor, a few small cervical lymph nodes (smaller than 0.5 cm in diameter, mobile and inflexible) and a mild splenomegaly (3 cm below costal margin).

The hematological profile was as follows: Ht 28.6%, Hb 8.7g/dL, (MCV 117 fL, MCH 33.9 pg, MCHC 30.4 g/dL), reticulocytes 2.5%, WBC 3.8×10<sup>9</sup>/L (neutrophils 46%, lymphocytes 38%, monocytes 15%, eosinophils 1%), platelet count 620×10<sup>9</sup>/L. Macrocytosis, anisocytosis, poikilocytosis and few giant platelets were observed on routine blood smears (figures 1, 2). Her biochemical profile was as follows: SGOT 30 IU/L, SGPT 45 IU/L, LDH 850 IU/L, glucose 1.0 g/dL, BUN 0.50 g/dL, creatinine 1.2 mg/dL, uric acid 7.5 g/dL, Na<sup>+</sup> 139 mEq/L, K<sup>+</sup> 4.0 mEq/L, Ca<sup>++</sup> 4.8 mEq/L, γ-GT 38 IU/L, total proteins 7.4 g/L, protein electrophoresis was normal. Serum vitamin B<sub>12</sub> was 450 ng/L, while serum folate was 8.3 μg/L. Serum Fe/ferritin levels were normal. Serum erythropoietin (EPO) concentration was 564 U/L. The bone marrow aspiration (figures 3–5) revealed an hypercellular marrow with erythroid hyperplasia

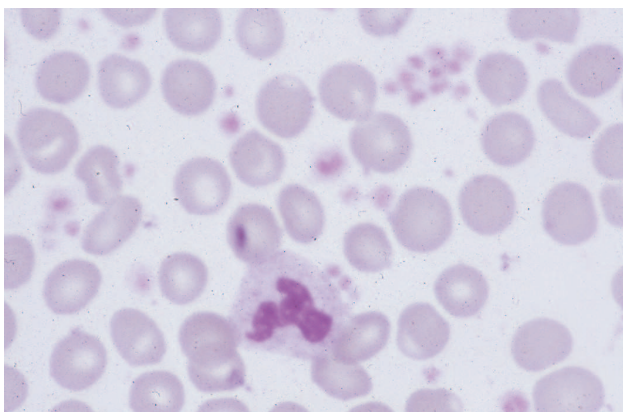


Figure 1

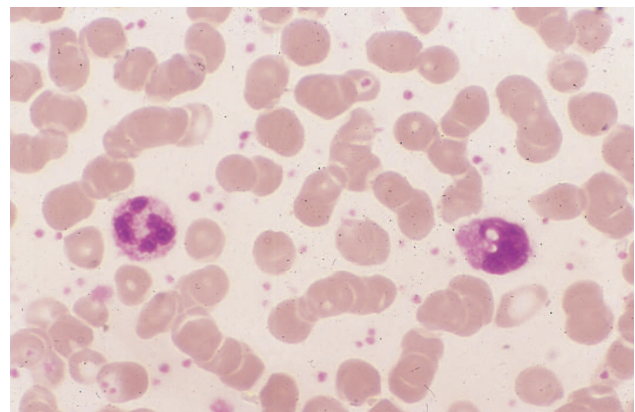


Figure 2

ARCHIVES OF HELLENIC MEDICINE 2017, 34(2):278–279  
ΑΡΧΕΙΑ ΕΛΛΗΝΙΚΗΣ ΙΑΤΡΙΚΗΣ 2017, 34(2):278–279

J.V. Asimakopoulos,  
L. Papageorgiou,  
V. Telonis,  
A. Zannou,  
P.M. Arapaki,  
T. Giannikos,  
M. Belia,  
E.F. Triantafyllou,  
E. Konstantinou,  
M. Efstathopoulou,  
G. Gainarou,  
E. Sinni,  
P. Tsaftaridis,  
E. Plata,  
T.P. Vassilakopoulos,  
M.K. Angelopoulou,  
K. Konstantopoulos,  
J. Meletis

*Hematology Department and Bone Marrow Transplantation Unit, National and Kapodistrian University of Athens, School of Medicine, "Laikon" General Hospital, Athens, Greece*

and megaloblastic and moderate dyserythropoietic changes. The myeloid series was normal, the blast count was less than 5% and many hypolobulated or unilobulated megakaryocytes with platelet clumps were also present. The cytogenetic analysis was characteristic in most of the bone marrow metaphases.

The patient was treated with EPO administration, on alternate days, at a dose of 150 U/kg, which was increased to 300 U/kg after 6 weeks. The EPO was given for 12 weeks without any effect.

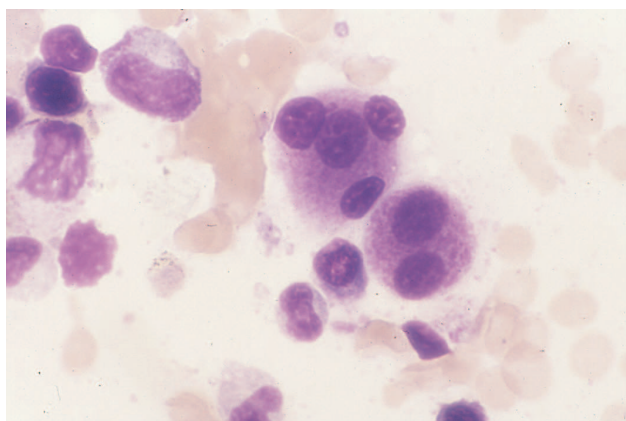


Figure 3

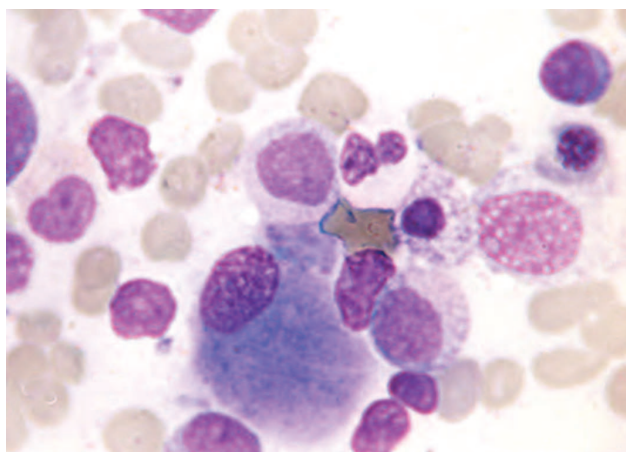


Figure 4

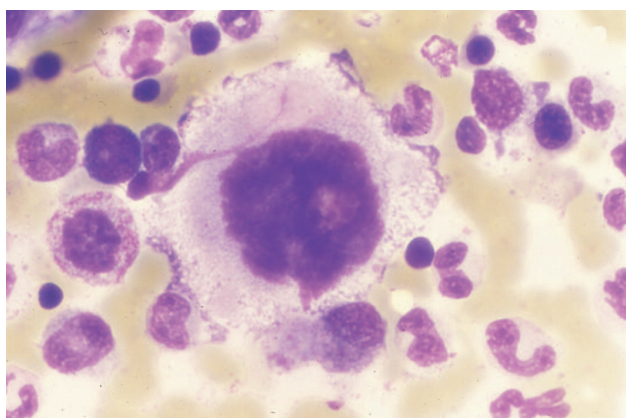


Figure 5

### Comment

In 5q- syndrome an association of refractory anemia with the presence of morphological abnormal megakaryocytes is present in

the bone marrow and long arm deletion of chromosome 5 (non-specific finding). Typically, the syndrome is frequent in persons (more frequent in women) over 60 years of age (<25% in persons less than 50 years of age, rarely in younger persons). Diagnosis is confirmed by caryotyping (non-specific finding because it may be associated with the other myelodysplastic syndromes).

The main manifestation is a progressive presence of a mild macrocytic anemia (hemoglobin less than 8 g/dL in 50% of cases), while thrombocytosis with a normal or mild decrease of WBC usually exists. There is also intense anisocytosis, poikilocytosis, as well as the presence of giant platelets in the peripheral blood smear.

There is an increased megakaryocytic number in the bone marrow, with frequent finding of micromegakaryocytes, with one nucleus or decreased nuclear lobes or containing a cleaved nucleus, or 2–3 lobes overlapped and abundant cytoplasm (platelet producing megakaryocytes). Mononuclear megakaryocytes may also be seen in CML, but they represent only a small percentage of megakaryocytes. Bone marrow cellularity varies and there is often an erythroid series hyperplasia. In *in vitro* cultures there is a normal CFU-GM growth but a diminished BFU-E growth. Clinically about 25% of the patients have splenomegaly.

The most frequent abnormality is related to the areas between 5q12 and 5q33 [more often *del(5)(q13q33)*] and in most cases the deletion of a region near the 5q22]. The GM-CSF, IL-3 and IL-5 related genes and M-CSF, platelet-derived growth factor and endothelial cell growth factor receptors are placed in this region. The abnormality is located mainly in the myeloid series cells and not in T lymphocytes, stromal cells and other cell types (main role of these factors synthesis). In addition to 5q- other abnormalities of chromosomes 3, 7, 8, 17 and 21 have been described (with an atypical syndrome and, rather, as having an acute leukemia or preleukemia).

### References

1. MELETIS J. *Atlas of hematology*. 3rd ed. Nireas Publ Inc, Athens, 2009:259–486
2. PELLAGATTI A, BOULTWOOD J. Recent advances in the 5q- syndrome. *Mediterr J Hematol Infect Dis* 2015, 7:e2015037
3. BUNN HF. 5q- and disordered haematopoiesis. *Clin Haematol* 1986, 15:1023–1035
4. SWOLIN B, WEINFELD A, RIDELL B, WALDENSTRÖM J, WESTIN J. On the 5q- deletion: Clinical and cytogenetic observations in ten patients and review of the literature. *Blood* 1981, 58:986–993
5. PADRON E, KOMROKJI R, LIST AF. Biology and treatment of the 5q- syndrome. *Expert Rev Hematol* 2011, 4:61–69
6. BOULTWOOD J, PELLAGATTI A, MCKENZIE AN, WAINSCOAT JS. Advances in the 5q- syndrome. *Blood* 2010, 116:5803–5811

Corresponding author:

J. Meletis, Hematology Department and Bone Marrow Transplantation Unit, National and Kapodistrian University of Athens, School of Medicine, "Laikon" General Hospital, Athens, Greece, tel.: +30 210 74 66 902, fax: +30 210 7456698  
e-mail: imeletis@med.uoa.gr

.....  
"Diagnosis: Myelodysplastic syndrome; "5q- syndrome"