

## CONTINUING MEDICAL EDUCATION ΣΥΝΕΧΙΖΟΜΕΝΗ ΙΑΤΡΙΚΗ ΕΚΠΑΙΔΕΥΣΗ

### Pediatric Radiology Quiz – Case 16

A 4-year-old child presented to the Emergency Department of our hospital due to abdominal pain for the last 24 hours. Physical examination showed abdomen tenderness. The child underwent ultrasound and X-ray examination of the abdomen, along with laboratory blood tests, with no remarkable findings. Its parents did not give any specific history of foreign body ingestion. The child was admitted to the hospital. After few hours, the child complained of abdominal pain worsening and physical examination revealed peritoneal irritation. The child was referred to the Computed Tomography (CT) Department for an emergency low dose abdomen CT, which showed free intraperitoneal air (figures 1 to 2), a sign for gastrointestinal perforation. The child underwent surgery that revealed perforation of transverse colon by a very small piece of wood. After surgery, parents mentioned that the family had eaten 5 days ago barbecued meat on wooden sticks.

#### Comment

*Gastrointestinal tract perforation can present acutely or in an indolent manner. Diagnosis is based on medical history, especially if there is report or suspicion of foreign body ingestion; in more complicated cases, diagnostic imaging test can contribute to the correct diagnosis by revealing the presence of extraluminal free air in the peritoneal cavity or in the retroperitoneum. Colon perforation is seldom reported when occurring from non-traumatic causes; however, it is an abdominal surgical emergency in the pediatric population.*

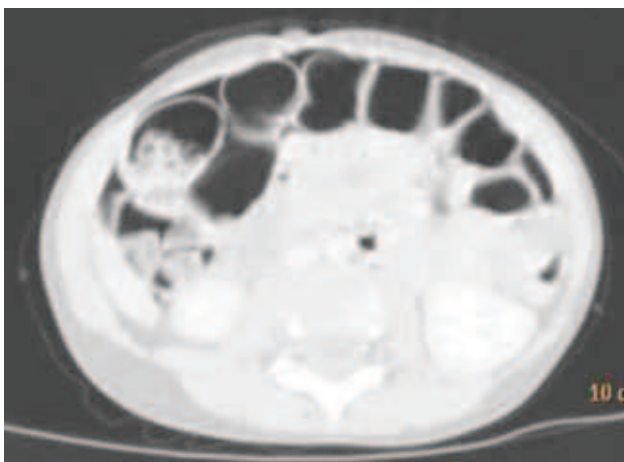


Figure 1

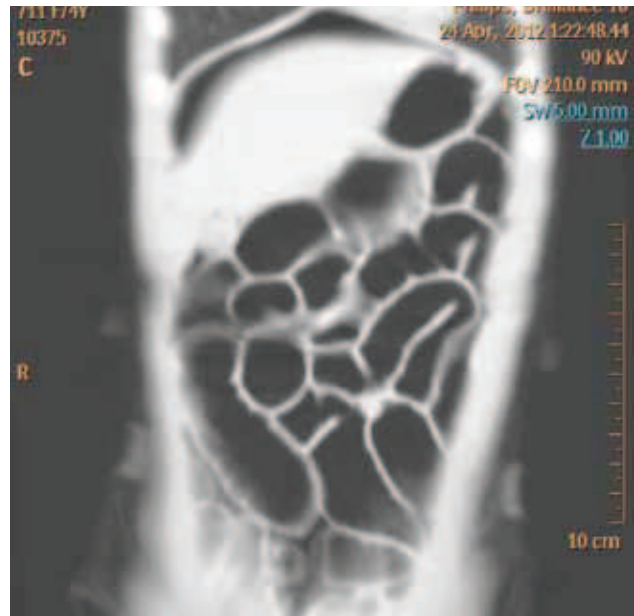

Figure 2

#### References

1. CHANG YJ, YAN DC, KONG MS, CHAO HC, HUANG CS, LAI JY. Non-traumatic colon perforation in children: A 10-year review. *Pediatr Surg Int* 2006, 22:665–669

#### Corresponding author:

T.N. Spyridopoulos, Department of Radiology, General Children's Hospital, Palea Penteli, Attiki and EchoHealth Pediatric and Adult Ultrasound Clinic, Athens, Greece  
Tel.: +30 210 7237476, e-mail: t.spyridopoulos@echohealth.gr

ARCHIVES OF HELLENIC MEDICINE 2016, 33(2):286  
ΑΡΧΕΙΑ ΕΛΛΗΝΙΚΗΣ ΙΑΤΡΙΚΗΣ 2016, 33(2):286

T.N. Spyridopoulos,<sup>1,3</sup>  
E. Christianakis,<sup>2</sup>  
I. Alexandrou,<sup>2</sup>  
N. Evlogias<sup>1</sup>

<sup>1</sup>Department of Radiology, General Children's Hospital, Palea Penteli, Attiki

<sup>2</sup>Department of Pediatric Surgery, General Children's Hospital, Palea Penteli, Attiki

<sup>3</sup>EchoHealth Pediatric and Adult Ultrasound Clinic, Athens, Greece

*Diagnosis: Colon perforation*