

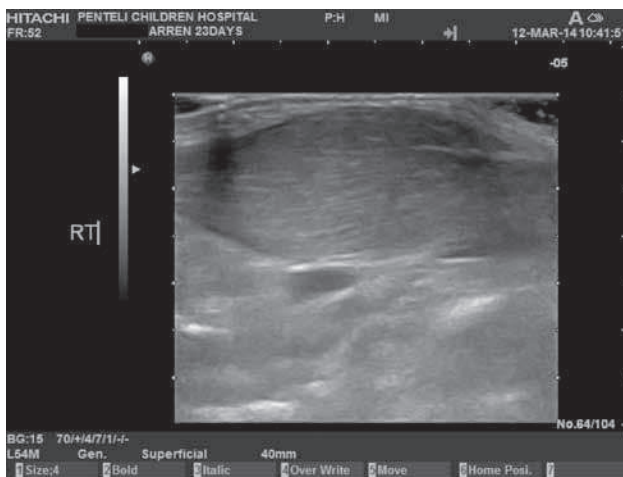## CONTINUING MEDICAL EDUCATION ΣΥΝΕΧΙΖΟΜΕΝΗ ΙΑΤΡΙΚΗ ΕΚΠΑΙΔΕΥΣΗ

### Pediatric Radiology Quiz – Case 11

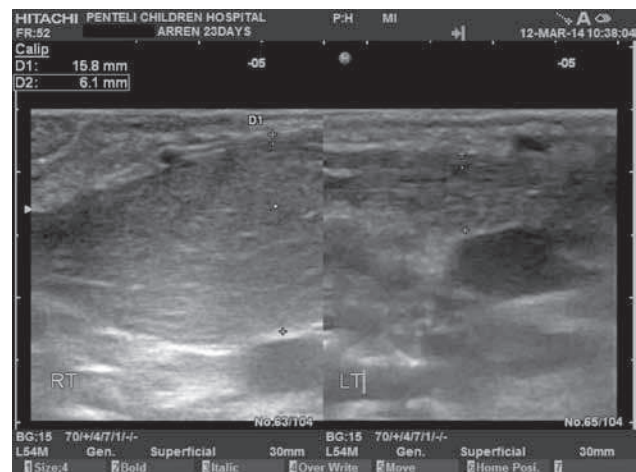
A 3-weeks-old, full-term born male infant presented to the Outpatient Department of our hospital. His parents noticed a non-tender, non-warm swelling on the right neck. His mother mentioned that she had a difficult birth, requiring vacuum extraction for delivery. Pediatric surgeons requested an ultrasound (US) of neck region, which revealed a diffuse enlargement of right middle sternocleidomastoid muscle (SCM). The enlarged area had the same echogenicity with the rest of the muscle, which had well-defined margins. The neck mass moved synchronously with the rest of the SCM during real time US examination. Color Doppler US of the SCM was unremarkable. Ultrasound findings were in line with the initial clinical diagnosis (figures 1, 2).

#### Comment

*Fibromatosis colli (FC) is the most common benign, non-inflammatory infant neck mass. The SCM is diffusely enlarged in a fusiform manner. One out of five affected infants has torticollis with the head tilt toward the affected side (most often the right side). The cause of the SCM pseudotumor of infancy is not clarified. Ultrasound is the imaging method of choice to verify the clinical diagnosis. Its treat-*



**Figure 1.** Ultrasound of right middle sternocleidomastoid (SCM) (longitudinal axis) shows a diffuse enlargement of the muscle in a fusiform manner. The enlarged area has homogenous echotexture and on real time ultrasonography (US) it moves synchronously with the rest of the muscle.



**Figure 2.** Comparison of the affected enlarged right sternocleidomastoid (SCM) with the normal sized left SCM.

*ment is conservative, since spontaneous resolution usually occurs by the completion of the first year of life.*

#### References

1. SHARMA S, MISHRA K, KHANNA G. Fibromatosis colli in infants. A cytologic study of eight cases. *Acta Cytol* 2003, 47:359–362
2. KUMAR V, PRABHU BV, CHATTOPADHAYAY A, NAGENDHAR MY. Bilateral sternocleidomastoid tumor of infancy. *Int J Pediatr Otorhinolaryngol* 2003, 67:673–675

*Corresponding author:*

T.N. Spyridopoulos, Department of Radiology, General Children's Hospital, Palea Penteli, Attiki, Greece  
e-mail: thspyrid@med.uoa.gr

**Diagnosis:** *Fibromatosis colli (infant sternocleidomastoid pseudotumor)*

ARCHIVES OF HELLENIC MEDICINE 2015, 32(2):251  
ΑΡΧΕΙΑ ΕΛΛΗΝΙΚΗΣ ΙΑΤΡΙΚΗΣ 2015, 32(2):251

T.N. Spyridopoulos,<sup>1</sup>  
E. Christianakis,<sup>2</sup>  
E. Lavda,<sup>1</sup>  
N. Evlogias<sup>1</sup>

<sup>1</sup>Department of Radiology, General Children's Hospital, Palea Penteli, Attiki  
<sup>2</sup>Department of Pediatric Surgery, General Children's Hospital, Palea Penteli, Attiki, Greece