

CONTINUING MEDICAL EDUCATION ΣΥΝΕΧΙΖΟΜΕΝΗ ΙΑΤΡΙΚΗ ΕΚΠΑΙΔΕΥΣΗ

Pediatric Radiology Quiz – Case 9

An 11-year-old boy presented to the Emergency Department of our hospital complaining for acute right lower limb pain. No history of trauma was mentioned. Physical examination revealed local tenderness just above the right ankle. X-rays showed a focal lucent cortical lesion with sclerotic lesions at the distal diaphysis of right tibia (figures 1a, 1b). A focused low dose computed tomography (CT) scan was performed in order to define the nature of this focal lesion (figures 2a, 2b). A cortical lesion (sized 27×15 mm) with sclerotic lobulated margins (internal scalloping) with no periosteal reaction or cortical lysis was observed, imaging findings consistent with nonossifying fibroma (NOF). The boy also underwent a magnetic resonance imaging (MRI) exam in a private diagnostic medical center (figures 3a, 3b, 3c).

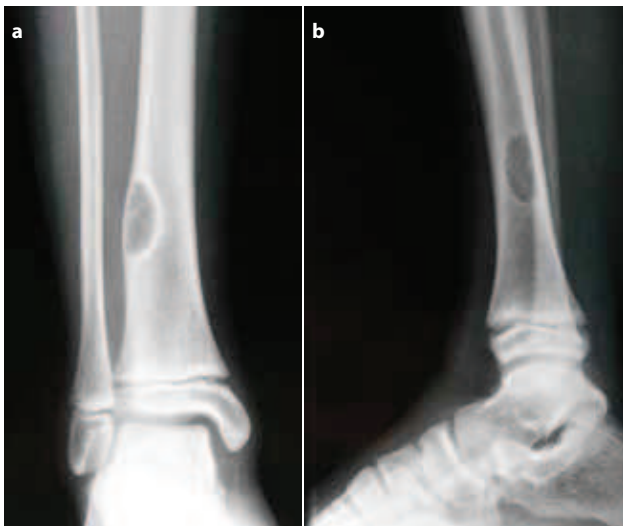

Figure 1a, 1b. Anteroposterior and lateral X-rays of right distal tibia. An eccentric cortical lesion with sclerotic margins is noted.

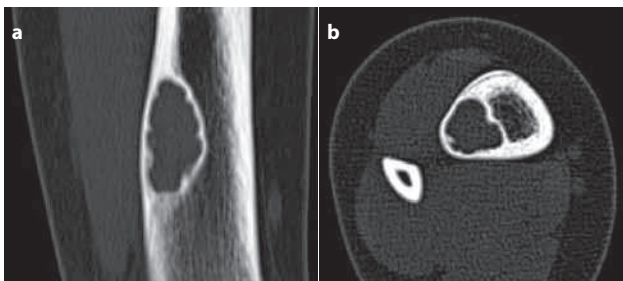


Figure 2a, 2b. Coronal and axial computed tomography (CT) view of distal right tibia: An eccentric cortical lesion with sclerotic margins, internal cortical scalloping. No periosteal reaction or cortical lysis is observed.

ARCHIVES OF HELLENIC MEDICINE 2014, 31(6):754
ΑΡΧΕΙΑ ΕΛΛΗΝΙΚΗΣ ΙΑΤΡΙΚΗΣ 2014, 31(6):754

T.N. Spyridopoulos,¹
M. Petra,²
S. Stathopoulou,¹
A. Stratigopoulou,¹
N. Evlogias¹

¹Department of Radiology, General Children's Hospital, Palea Penteli
²Department of Orthopedic Surgery, General Children's Hospital, Palea Penteli, Greece

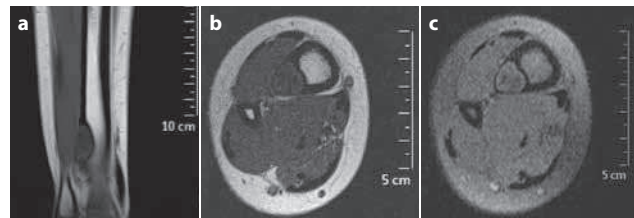


Figure 3a, 3b, 3c. Magnetic resonance imaging (MRI) views showing a low signal relatively homogeneous lesion in the lateral aspect of distal tibial diaphysis, compatible with fibrous or cartilage-type tissue; (a) T1 coronal, (b) T1 axial, (c) PD axial.

Comment

NOF is among the most common bone lesions encountered by radiologists. This lesion is found mostly in children. They are developmental defects that heal with sclerosis and eventually disappear around second to third decade of life. If the patient is older than 30 years, NOF should not be included in the differential diagnosis. Fibrous cortical defect (FCD) is a common synonym, histologically identical with NOF; however, FCD being smaller than 2 cm, while NOF is larger than 2 cm. These benign cortical lesions typically occur in the metaphysis of long bones, most commonly in the femur, followed by the tibia. They are commonly asymptomatic without periostitis, unless being complicated with fracture. It is important to recognize such lesions, because they are “don't touch lesions”, that means the radiologists should have the final word. CT and MRI may show interruption of the cortex, which represents cortical replacement by benign fibrous tissue.

References

1. BETSY M, KUPERSMITH LM, SPRINGFIELD DS. Metaphyseal fibrous defects. *J Am Acad Orthop Surg* 2004, 12:89–95
2. WOOTTON-GORGES SL. MR imaging of primary bone tumors and tumor-like conditions in children. *Magn Reson Imaging Clin North Am* 2009, 17:469–487

Corresponding author:

T.N. Spyridopoulos, Department of Radiology, General Children's Hospital, Palea Penteli, Greece
e-mail: thspyrid@med.uoa.gr

Diagnosis: Nonossifying fibroma