

## CONTINUING MEDICAL EDUCATION ΣΥΝΕΧΙΖΟΜΕΝΗ ΙΑΤΡΙΚΗ ΕΚΠΑΙΔΕΥΣΗ

### Electrocardiogram Quiz – Case 12

An 84-year-old woman presented to the emergency department of our hospital with a history consistent with exertional dyspnea of a few hours duration. The patient's personal history included arterial hypertension under ramipril, dyslipidemia under rosuvastatin and type 2 diabetes mellitus under metformin. At the emergency department she was hemodynamically stable. The 12-lead surface ECG revealed atrial fibrillation with a rapid ventricular response (fig. 1). Cardiac enzymes were positive, so the diagnosis of non-ST elevation myocardial infarction was set. On admission, the patient's ECG changed to those depicted below (fig. 2).

#### Questions

- What is the basic rhythm depicted on the 12-lead ECGs?
- What is the clinical significance of the depicted rhythm abnormalities?

ARCHIVES OF HELLENIC MEDICINE 2013, 30(4):509–510  
ΑΡΧΕΙΑ ΕΛΛΗΝΙΚΗΣ ΙΑΤΡΙΚΗΣ 2013, 30(4):509–510

E. Petrou,  
S. Chatzi,  
M. Boutsikou,  
A. Tsipis,  
V. Vartela,  
S. Mavrogeni,  
C. Girasis,  
I. Iakovou,  
G. Pavlides

Division of Cardiology, "Onassis" Cardiac  
Surgery Center, Athens, Greece

#### Comment

*Accelerated idioventricular rhythm (AIVR) is a ventricular rhythm consisting of three or more consecutive monomorphic beats, with gradual onset. Historically, since 1925 when Sir Thomas Lewis presented the first ECG trace of AIVR, however failing to identify it as an independent arrhythmia, different terminology has been used to describe it including non-paroxysmal ventricular tachycardia (VT),*

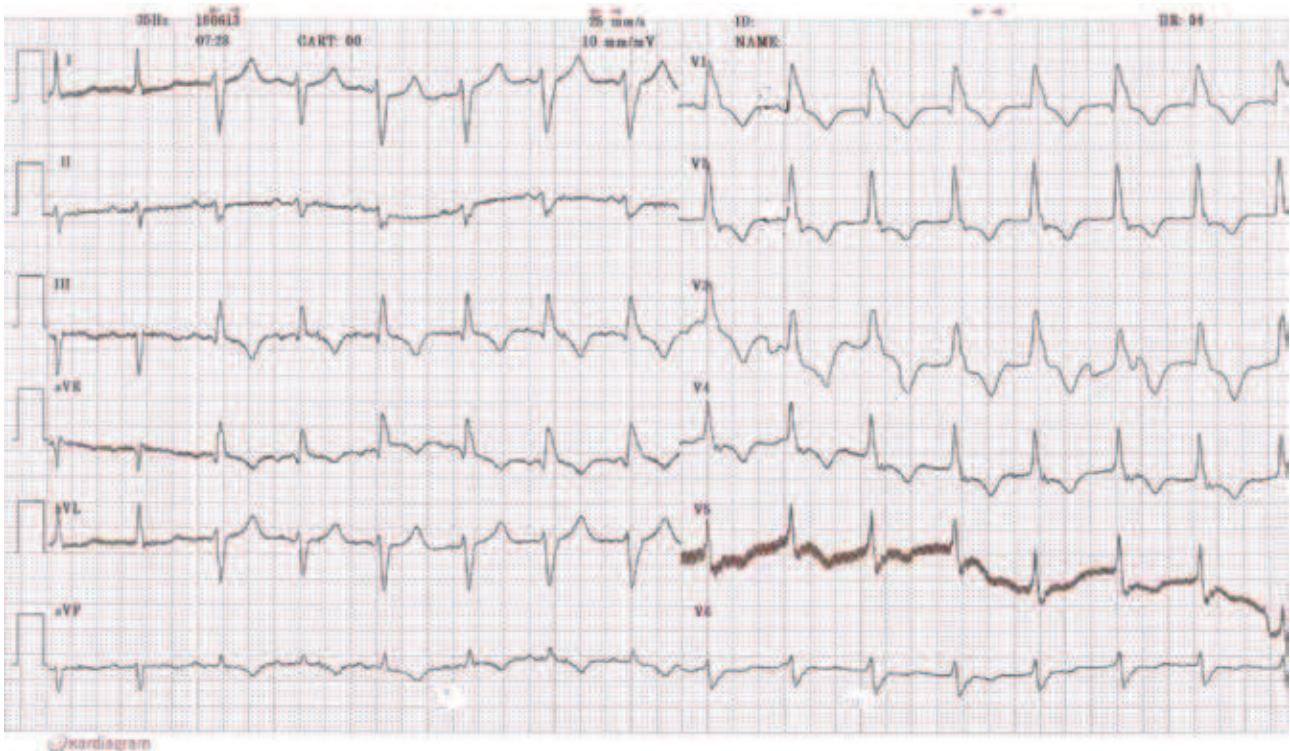
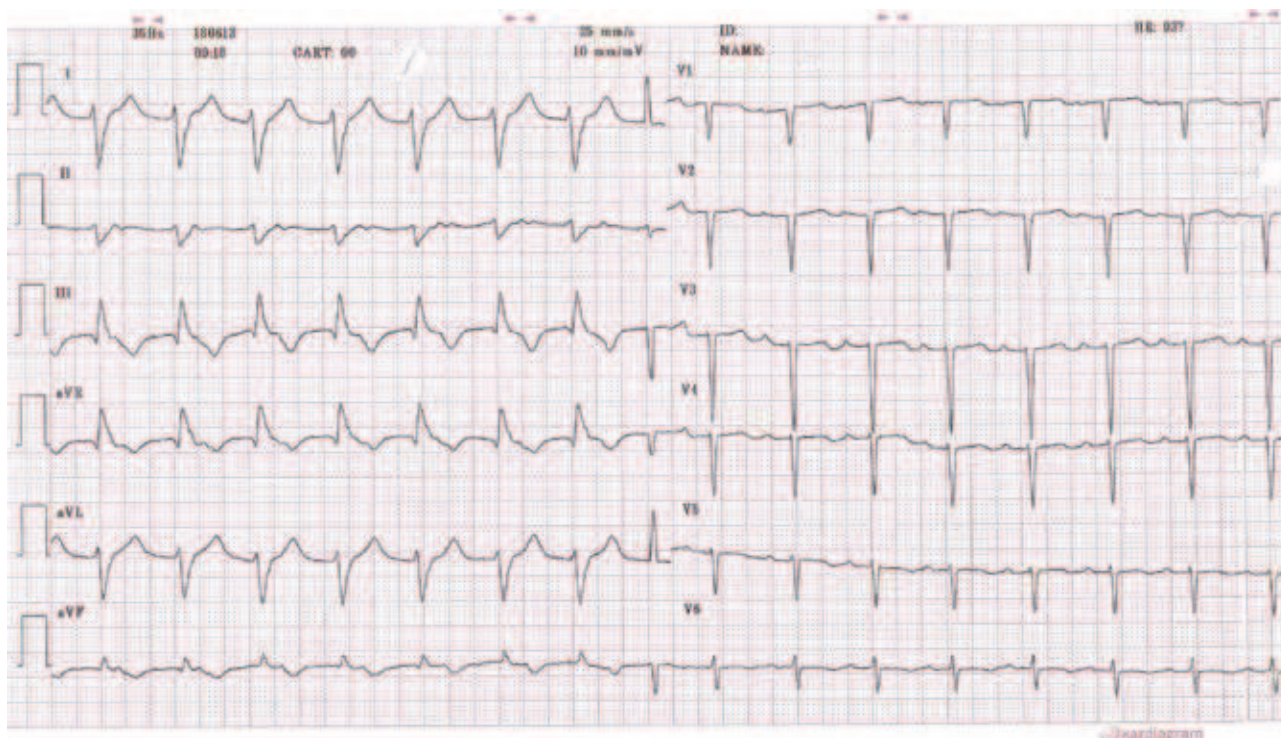


Figure 1



**Figure 1**

isorhythmic slow VT, and benevolent tachycardia. It can originate from the His bundle, the Purkinje system or the working contractile ventricular cells. Less commonly, AIVR is polymorphic. The discharge rate of the ectopic focus is similar to the sinus rate (isorhythmic) between 50 and 120 bpm. The ectopic focus manifests when the sinus rate slows down (below the ectopic focus) or when the ectopic focus accelerates above the intrinsic rate by 30–40 bpm. When both discharge rates (sinus and ectopic focus) are similar, isorhythmic dissociation, fusion and capture beats can be seen.

AIVR causes include: reperfusion phase of an acute myocardial infarction, drug toxicity (especially digoxin, cocaine and volatile anaesthetics), electrolyte abnormalities, cardiomyopathy, congenital heart disease, myocarditis, return of spontaneous circulation (ROSC) following cardiac arrest and athletic heart.

AIVR is usually a benign and well-tolerated arrhythmia. In most cases no treatment will be required and in rare situations such as sustained or incessant AIVR or when AV dissociation induces syncope, the risk of sudden death is higher, and the arrhythmia should be treated.

The main electrophysiological mechanism involved in AIVR is an abnormal calcium-dependent automatism (ectopic automaticity) that affects phase 4 of action potential (diastolic depolarization). When AIVR is associated with digitalis intoxication, the main arrhythmogenic mechanism involved is triggered activity.

Our patient underwent an uneventful coronary angiography that revealed a 70% stenosis at the middle part of the left anterior descending branch for which angioplasty and stenting was performed.

In conclusion, AIVR comprises an intriguing arrhythmia that

could manifest in several clinical scenarios. There are benign forms in subjects with no structural heart disease in which case, it usually requires no intervention, but sometimes it can present as a more severe arrhythmia, requiring treatment.

## References

1. DELISE P, D'ESTE D, MONICO E, MILLOSEVICH P, RAVIELE A, DAINESE F ET AL. Accelerated idioventricular rhythm with isorhythmic A-V dissociation. An electrophysiological study (author's translation). *G Ital Cardiol* 1980, 10:1588–1593
2. TATU-CHIȚOIU G. Non-paroxysmal ventricular tachycardia with isorhythmic atrioventricular dissociation. *Rom J Intern Med* 1991, 29:139–143
3. MOROZ VM, LIPNITSKII TN. Study of pathogenesis of ventricular arrhythmia in experimental rats by separation of sinus and ventricular substitutional rhythms. *Bull Exp Biol Med* 2006, 141:400–403
4. OSMANCIK PP, STROS P, HERMAN D. In-hospital arrhythmias in patients with acute myocardial infarction – the relation to the reperfusion strategy and their prognostic impact. *Acute Card Care* 2008, 10:15–25

Corresponding author:

E.G. Petrou, Division of Cardiology, "Onassis" Cardiac Surgery Center, 356 Sygrou Ave., GR-176 74 Kallithea, Greece  
e-mail: emmgpetrou@hotmail.com

**Diagnosis:** Accelerated idioventricular rhythm (AIVR)