

CONTINUING MEDICAL EDUCATION ΣΥΝΕΧΙΖΟΜΕΝΗ ΙΑΤΡΙΚΗ ΕΚΠΑΙΔΕΥΣΗ

Electrocardiogram Quiz – Case 10

A 71-year-old woman was admitted to our hospital in order to undergo a scheduled coronary angiography due to a history consistent with exertional dyspnea and a positive for cardiac ischemia exercise test. The patient's personal history included arterial hypertension under telmisartan and dyslipidemia under atorvastatin. The initial 12-lead surface ECG is depicted below (fig. 1). However, just before the patient's entrance to the cath lab, the corresponding author of the present quiz ordered a new surface ECG be performed in his presence (fig. 2).

ARCHIVES OF HELLENIC MEDICINE 2013, 30(3):375–377
ΑΡΧΕΙΑ ΕΛΛΗΝΙΚΗΣ ΙΑΤΡΙΚΗΣ 2013, 30(3):375–377

**E. Petrou,
M. Boutsikou,
A. Tsipis,
A. Katsianis,
I. Fekos,
V. Vartela,
S. Mavrogeni,
C. Girasis,
I. Iakovou,
G. Pavlides**

*Division of Cardiology, "Onassis" Cardiac
Surgery Center, Athens, Greece*

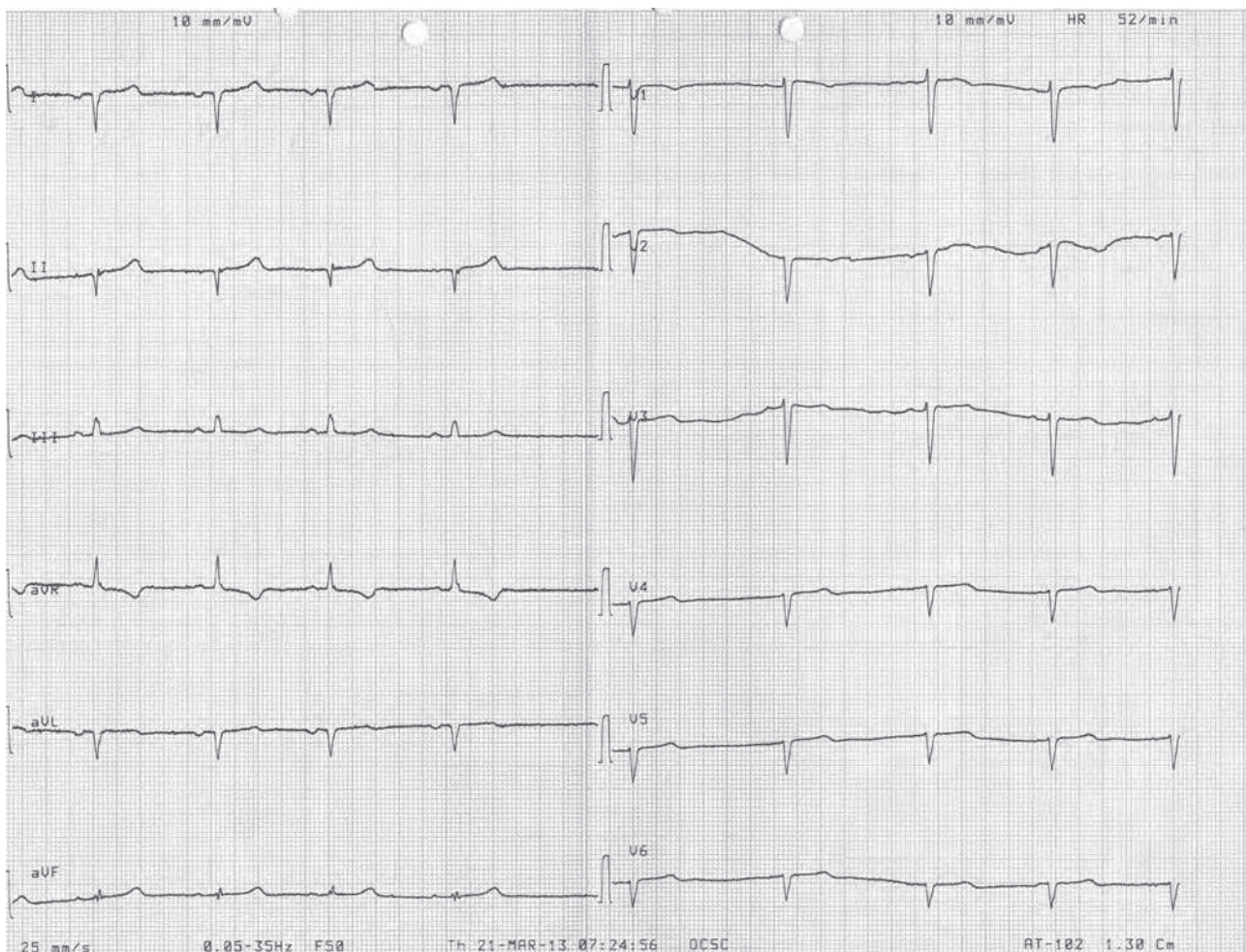


Figure 1

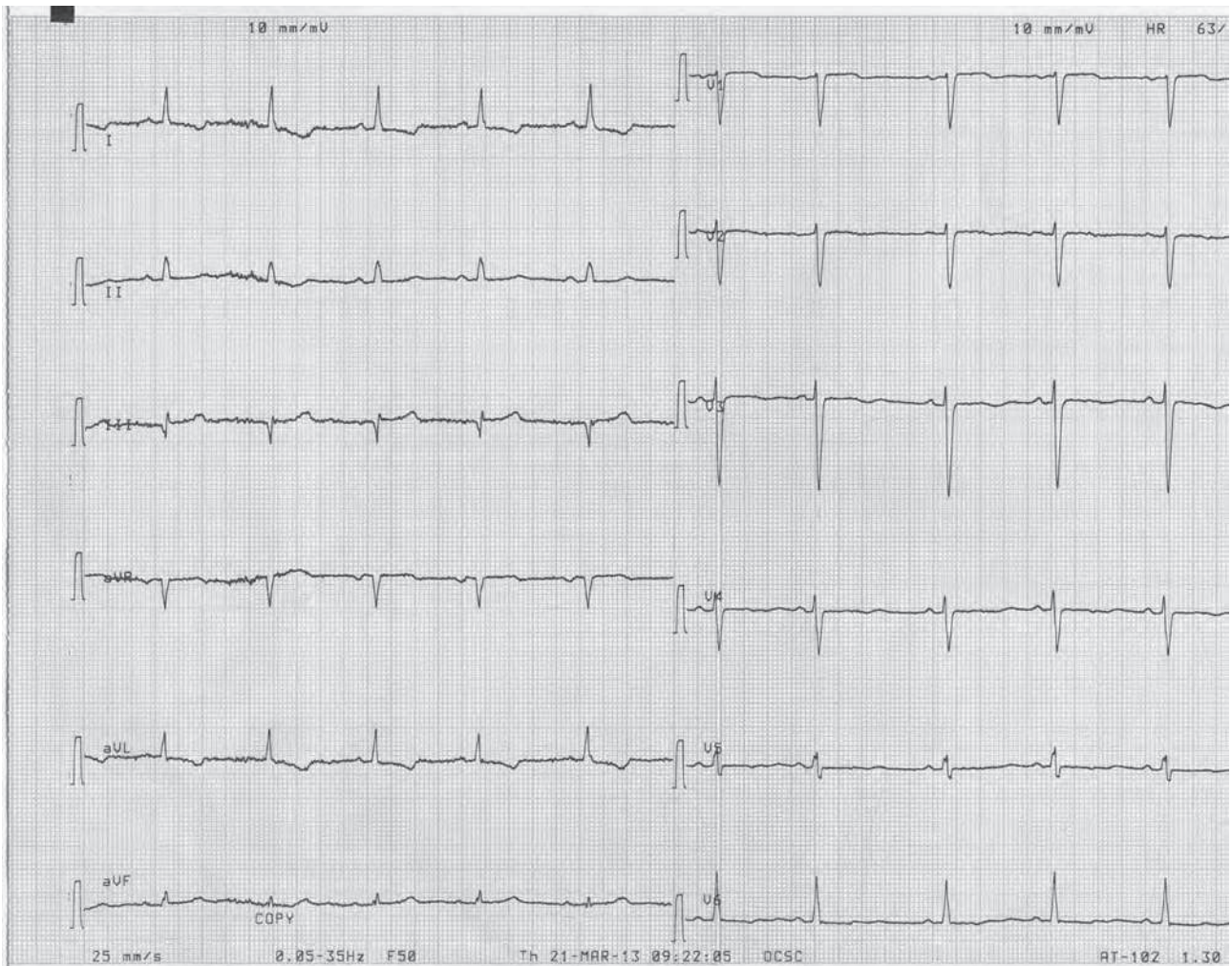


Figure 2

Questions

- What could be the reason for the corresponding author's order?
- What is the clinical significance of the two ECGs' differences?

Comment

Dextrocardia is a rare cardiac anomaly in which the heart is located in the right hemithorax with the axis directed to the right and caudally, believed to occur in approximately 1 in 12,000 people. There are two main types of dextrocardia: Dextrocardia of embryonic arrest (also known as isolated dextrocardia) which is commonly associated with severe defects of the heart and related abnormalities, including pulmonary hypoplasia, and dextrocardia situs inversus. The latter is further divided into dextrocardia situs inversus solitus, referring to the heart being a mirror image situated on the right side and dextrocardia situs inversus totalis, in which additionally to the heart, internal organs of the thorax and the abdomen are also

positioned on the opposite side. The condition should be distinguished from other anatomical variations such as dextroposition, referring to heart displacement to the right hemithorax due to deformities of chest wall, deformities of the diaphragm, postpneumonectomy, hypoplastic right lung, eventration of the diaphragm, left hemidiaphragmatic paralysis, and pneumomediastinum, mesocardia, in which the heart is placed in the midline of the thorax, heterotaxy (and situs ambiguous), in which thoracic and abdominal organs are placed abnormally, with no right-left relationship. Associated cardiac malformations include common atrioventricular canal, univentricular heart, transposition of the great arteries, and total anomalous pulmonary venous return. Moreover, 15% of patients with dextrocardia and situs inversus are known to suffer from Kartagener's syndrome (immotile cilia syndrome).

In mirror-image dextrocardia, the axes of P, QRS and T waves are directed to the right and inferior. This results in positive P waves in leads III and aVF, as well as negative P waves in leads I and aVL. Not only the P wave, but QRS complex and T waves are also negative in lead I, and low voltage in leads V3–V6 can be observed. Furthermore,

in dextrocardia, normal progression of the R wave is not observed in chest leads. The differential diagnosis includes arms leads reversal, in which P waves become negative in lead I and positive in lead aVR. In this condition, the QRS complex and T wave are also negative in lead I. However, reversal of arms leads does not affect R progression in chest leads and results in an increase in R wave amplitude. In a patient with dextrocardia, it is easier to comment on the ECG if the chest electrodes are symmetrically placed on the right chest and the arm leads are reversed. It is also important to mark the right orientation of the leads on the ECG strip.

Coronary angiography for dextrocardia was first reported in 1974 in a patient who underwent aneurysmectomy. Coronary artery bypass surgery in a patient with dextrocardia was first described in 1982, and coronary grafting with a right mammary artery was reported in 1988. As for percutaneous coronary interventions techniques, the first two patients undergoing coronary angioplasty were reported in 1987 and 1989, respectively.

With the use of Judkins catheters, standard image acquisition, and counter rotation of catheters, our patient underwent an uneventful coronary angiography that revealed normal coronary arteries. A chest x-ray and an older chest and abdomen CT scan confirmed the solitus nature of the dextrocardia.

In conclusion, dextrocardia comprises a very rare developmental irregularity that requires the proper attention. The fact that even in our specialized, quaternary cardiac centre a patient reached the cath lab with a completely unacceptable ECG emphasizes the need for dextrocardia consideration by the paramedical staff, let alone the treating physician.

References

1. MALDJIAN PD, SARIC M. Approach to dextrocardia in adults: Review. *AJR Am J Roentgenol* 2007, 188(Suppl 6):S39–S49
2. DHANJAL TS, DAVISON P, COTTON JM. Primary percutaneous coronary intervention for acute myocardial infarction in a patient with dextrocardia. *Cardiol J* 2009, 16:168–171
3. MARTA MJ, FALCÃO LM, SAAVEDRA JA, RAVARA L. A case of complete situs inversus. *Rev Port Cardiol* 2003, 22:91–104

Corresponding author:

E.G. Petrou, Division of Cardiology, "Onassis" Cardiac Surgery Center, 356 Sygrou Ave., GR-176 74 Kallithea, Greece
e-mail: emmgpetrou@hotmail.com