

ORIGINAL PAPER  
ΕΡΕΥΝΗΤΙΚΗ ΕΡΓΑΣΙΑ

**Clinical findings of thyroid cancer  
in 288 Japanese  
Early soft tissue and bone metastases  
with raised serum thyroglobulin (Tg)  
in follicular and undifferentiated types**

**OBJECTIVE** Investigation of the clinical findings in 661 Japanese patients with thyroid nodules, of which 288 (44%) were malignant. **METHOD AND RESULTS** Of the 288 malignant thyroid nodules, histological examination showed papillary carcinoma (Ca) in 249 (86.5%), follicular Ca in 28 (9.7%), undifferentiated Ca in 4 (1.4%), and medullary Ca in 7 (2.4%). Even among the 104 cases of papillary Ca with normal serum levels of thyroglobulin (Tg) (4–78 ng/mL), microscopic cervical lymph node (CLN) metastases were identified in 84% at thyroidectomy. All 28 cases of papillary Ca with Tg >500 ng/mL showed extra-thyroid metastases, and an anti-Tg antibody level of  $\geq 100$  U/mL was detected in 10. High Tg secretion (>10,000 ng/mL) from soft tissue, bone or lung metastases was detected in 9 (32%) cases of follicular Ca and in 2 (50%) of undifferentiated Ca, in which metastatic curettage improved the clinical findings. Tg levels of 4,000–10,000 ng/mL were observed in 7 (25%) cases of follicular Ca and 1 (25%) of undifferentiated Ca. One elderly female with follicular Ca and Tg >10,000 ng/mL developed bone marrow dysplasia with proliferation of p53- and CD163-positive macrophages and peripheral pancytopenia 28.5 years after the diagnosis of thyroid Ca. Patients with follicular Ca with relatively low Tg of <2,000 ng/mL more commonly exhibited early lung metastases. The thyroid Ca, in 12 (4.8%) patients with papillary Ca and 1 (3.6%) with follicular Ca suspected of Cowden syndrome (CS), was associated with bilateral breast Ca, with a good prognosis, apart from 2 cases with high Tg levels (673 and 704 ng/mL). **CONCLUSIONS** Thyroid Ca had very early extra-thyroid metastases but a long survival rate.

Thyroid carcinoma (Ca) is a common cancer gradually increasing in prevalence globally. In the US, the annual incidence of thyroid Ca was reported to have increased 2.6-fold between 1980–1997 and 1997–2006, with disease persistence and disease-specific death rates of 17.1% and 1.3%, respectively.<sup>1</sup> Although in Italy the population with differentiated thyroid Ca (DTC) showed mild iodine deficiency in the period 1997–2005, but normal iodine status in 2006–2010, tumor-associated thyroiditis was 10% higher in the 2006–2010 period.<sup>2</sup> In the 1980s the technique of radioisotope (RI) iodine (<sup>131</sup>I) ablation was developed gradually to eradicate thyroid Ca remnants in DTC. With the introduction of serum thyroglobulin (Tg) measurement after stimulation with recombinant human thyroid-stimulating

hormone (rhTSH), neck ultrasound (US) evaluation, and improved imaging information obtained from whole-body scintigraphy with <sup>131</sup>I and 18F-fluoro-deoxyglucose-positron emission tomography (FDG-PET) uptake, the diagnosis and prognosis of thyroid Ca improved globally.

In 1963, Cowden syndrome (CS) was first reported as a multisystem disease characterized by macrocephaly, a variety of cancers and skin, neurological, and gastrointestinal manifestations. Mutations have been identified in the phosphatase and tensin homolog (PTEN), a tumor suppressor gene located on 10q23.3, which is a key negative regulator of the phosphatidylinositol-3-kinase (PI3K) signal transduction cascade, in many cases of CS.<sup>3</sup> As CS has PTEN mutations it is also called PTEN hamartoma tumor

ARCHIVES OF HELLENIC MEDICINE 2013, 30(3):299–308  
ΑΡΧΕΙΑ ΕΛΛΗΝΙΚΗΣ ΙΑΤΡΙΚΗΣ 2013, 30(3):299–308

**T. Nakatsuji**

*Department of Transfusion Cell Therapy,  
Hamamatsu University, School of  
Medicine, Hamamatsu, Japan*

Κλινικά ευρήματα καρκίνου του  
θυρεοειδούς σε 288 Ιάπωνες:  
Πρώιμες μεταστάσεις οστών  
και μαλακών μορίων με αύξηση  
της θυρεοσφαιρίνης ορού σε  
θυλακιώδη και αδιαφοροποίητο  
τύπο καρκίνου

*Περίληψη στο τέλος του άρθρου*

**Key words**

Bone, soft tissue metastasis  
Breast cancer  
Cervical lymph node metastasis  
Metastatic cancer activation  
Serum thyroglobulin  
Thyroid cancer

*Submitted 8.10.2012  
Accepted 26.11.2012*

syndrome (PHTS). The multiple mucocutaneous lesions of CS are associated with goiter, thyroid Ca, fibrocystic breast disease, breast Ca, endometrial Ca, gastrointestinal polyps, gastrointestinal Ca and skin lesions.<sup>4</sup>

In this study, the clinical findings in 288 Japanese patients with histologically confirmed thyroid Ca were analyzed. The study population was derived from 661 consecutive patients presenting with thyroid nodules, on the basis of the histopathological findings. The clinical data were recorded and analyzed as follows: Thyroid Ca metastases to cervical lymph nodes (CLN), bilateral breast Ca, related to thyroid Ca, correlation between serum levels of Tg and high malignancy, and clinical features of undifferentiated and follicular thyroid Ca. Improvement of iodine radioisotope therapy (RIT) in DTC was also discussed on the basis of these study findings.

## **MATERIAL AND METHOD (PRE-ANALYZING CLINICAL DATA)**

From 1996 to 2012, the study population was selected from a series of 661 patients with thyroid nodules who were admitted to the hospital of the Hamamatsu University School of Medicine in Japan, by first histopathological and subsequently clinical and radiological examination. Of the 661 patients, 501 were females and 160 males; a female to male ratio of 3.1. After excluding 373 patients in whom the lesions were goiters, cysts, follicular adenomata, secondary cancer metastases to the thyroid gland, malignant lymphoma, Hashimoto's disease or Basedow disease, 288 patients with primary thyroid Ca were selected and their relevant data were analyzed as the focus of this study. In these 288 patients primary thyroid Ca was diagnosed definitively by histopathological findings with the help of clinical records. In this group, 209 were females and 70 males, with a female to male ratio of 2.6, while thyroid nodules of non-primary thyroid Ca were observed at a female to male ratio of 3.7. Females thus had higher rates of both primary and non-primary thyroid Ca. The histopathological data, including immunochemical antibody (Ab) staining, were provided by the Department of Clinical Pathology. The morphological picture of thyroid Ca in the sample was not simple; it was sometimes a mixed type, and there was a tendency to change to higher grades of malignancy during long clinical courses. For this reason the serum levels of Tg were also used to determine the type of thyroid Ca in this study. High levels of Tg suggested worse microscopic findings. Thyroid Ca was classified into papillary Ca in 249 patients (86.5%), follicular Ca in 28 (9.7%), undifferentiated (poorly differentiated) Ca in 4 (1.4%), and medullary Ca in 7 (2.4%). The average age of the patients in 2012 was 64±15 years in the females and 66±15 years in the males, of which 18 females and 6 males were aged under 40 years. Serum Tg was determined in 224 cases of papillary Ca, 28 of follicular Ca, 4 of undifferentiated Ca and 2 of medullary Ca. Serum Tg was

measured in the central laboratory of the hospital by electrochemiluminescent immunoassay (ECLIA) using a sandwich method, in which Modular Analytics EE (E170) (Roche Diagnostic Systems Corporation, Tokyo, Japan) was applied for the measurement. The normal range for serum Tg was 4 to 78 ng/mL. Anti-Tg Ab was measured by radioimmunoassay (RIA), with a normal range of ≤0.3 U/mL, and was confirmed in 123 cases of papillary Ca including 6 with breast Ca and 15 with Tg levels of 500–<2,000 ng/mL, suspected of co-existent chronic thyroiditis. Among these, 108 had levels of Tg <500 ng/mL, and 2 had no Tg measurement. Of 28 cases with follicular Ca, 15 were examined for anti-Tg Ab, among which only 1 case with breast Ca was included. In all 4 cases of undifferentiated Ca anti-Tg Ab was measured. As bilateral breast Ca was found in 12 patients with papillary Ca and 1 with follicular Ca, carbohydrate antigen 15-3 (CA15-3) and breast Ca antigen 225 (BCA225) were examined. CA15-3 was measured by ECLIA as described above, and BCA225 was measured by enzyme immunoassay (EIA). The normal ranges of CA15-3 and BCA225 were <27 U/mL and <160 U/mL, respectively. Clinical treatment consisting of mastectomy, thyroidectomy, and lung lobectomy were performed by the surgeons and otolaryngologists of this hospital when indicated. Radical removal of CLNs was usually combined with thyroidectomy. CLN histopathological examination showed no metastasis in several cases, specifically 51 papillary Ca (18%), 8 follicular Ca (29%), 2 undifferentiated Ca (50%), and 4 medullary Ca (57%). CLN metastasis was detected in 198 cases of papillary Ca, 20 of follicular Ca, 2 of undifferentiated Ca and 3 of medullary Ca. Among the 129 cases of papillary Ca with only normal Tg levels, 104 had microscopic CLN findings. Soft tissue metastatic tumor resection close to bone and bone was carried out by orthopedic surgeons. Following thyroidectomy, intra-body radiation therapy (IBRT) with RI <sup>131</sup>I ablation was administered by the hospital radiologists from 1990 onwards. A typical course of IBRT with <sup>131</sup>I ablation was as follows: At 1–2 months post-total thyroidectomy, <sup>131</sup>I of 4.7–7.4 GBq (100–200 mCi) is given as the first IBRT treatment. Every 6 months to 1 year, <sup>131</sup>I of 111–165 MBq (3–5 mCi) is given as subsequent IBRT treatment. When there is no <sup>131</sup>I uptake, the IBRT is stopped. After IBRT with <sup>131</sup>I, thyroid Ca metastasis is investigated by whole-body scintigraphy (scan) and single-photon emission computed tomography (SPECT)/computed tomography (CT). For the investigation of thyroid Ca metastasis, 18F-labeled 2-fluoro-2-deoxy-D-glucose (FDG) positron emission tomography (PET) was also applied. Thyroid hormone (TH) replacement was administered by the internal medicine physicians.

## **RESULTS**

Table 1 shows a summary of thyroid Ca found in the 288 patients. Papillary Ca was the most common type, numbering 249 (86.5%). Follicular Ca was found in 28 (9.7%) patients, including 2 with a variant of follicular Ca. Some cases were found of mixed follicular and papillary Ca. Undifferentiated Ca was diagnosed in 4 cases (1.4%) and medullary Ca in 7 (2.4%). The 2 females with medul-

**Table 1.** Primary thyroid cancers (Ca) found in 288 (44%) patients, among 661 patients presenting with thyroid nodules.

Type of Ca	Total number (%)	F to M (ratio)	CLN metastasis (%)
Papillary	249 (86.5)	188/61 (3.1)	86*
Follicular	28 (9.7)	16/12 (1.3)	75
Undifferentiated	4 (1.4)	2/2 (1.0)	100
Medullary	7 (2.4)	3/4 (0.8)	100

F to M: Female to male, CLN: Cervical lymph node

\* In the 104 patients with normal levels of thyroglobulin (Tg) the metastasis rate was 84%. Among 129 patients with papillary Ca and normal Tg levels, 104 patients were evaluated for microscopic CLN metastasis.

lary Ca had associated adrenal pheochromocytoma, that is, multiple endocrine neoplasia (MEN), type 2. The female to male ratio of papillary Ca was the highest, at 3.1, followed by 1.3 for follicular Ca. Undifferentiated Ca and medullary Ca had female to male ratios of 1.0 and 0.8, respectively. In highly malignant cases, the female to male ratios became lower. The rate of CLN metastasis ranged from 75% to 100%. The CLN metastatic rate of 75% in follicular Ca was lower than the 86% of papillary Ca. Among 129 patients with papillary Ca who had Tg levels of only  $\leq 78$  ng/mL (normal values) throughout their entire clinical courses, 104 patients were evaluated for microscopic CLN metastasis at thyroidectomy, of whom 87 (84%) exhibited microscopic CLN metastases.

Many females with thyroid Ca had various pathological findings in the breasts, uterus, and ovary. Although hyper-trophic lesions were a major common finding, 12 cases of papillary Ca and 1 case of follicular Ca were associated with ductal Ca of the breast in females. The average age at thyroidectomy or thyroid Ca diagnosis was  $52 \pm 12$  years, ranging from 27 to 72 years. Table 2 summarizes the clinical features of the 7 females who showed both thyroid

papillary Ca and breast ductal Ca. In 4 patients, estrogen receptor (ER) and progesterone receptor (PgR) expression on the breast Ca was examined by immunochemical Ab staining. ER was positive in all 4 cases (table 2, nos 4, 5, and 7), and in another case not listed in table 2, but only 50% were positive for PgR (table 2, nos 5 and 7). Human epidermal growth factor receptor type 2 (HRR2) proteins were not found in the one case not listed in table 2. Apart from 2 cases that showed Tg of 637 and 704 ng/mL, the latter with follicular Ca, Tg values were normal in the other 7 cases. Anti-Tg Ab was measured in 7 cases (table 2, nos 2, 3, 4, and 5, and 3 other cases). No 4 and No 5 had anti-Tg Ab levels of 2.9 and 7.3 U/mL, respectively, only at the onset of thyroid cancer. One case of follicular Ca had anti-Tg Ab of 17 U/mL, also at the onset. The anti-Tg Ab in the other 4 cases was  $\leq 0.3$  U/mL. Of the 13 females with breast Ca, 7 underwent mastectomy before thyroidectomy, and 6 after thyroidectomy. The cancer must have developed in the two sites at almost the same time. The levels of CA15-3 (and BCA225) were within the normal range pre-mastectomy in all the 7 (6) cases listed in table 2. After right or left mastectomy, there was no case with elevated CA15-3 and BCA225. Apart from the 2 cases with high Tg, double thyroid and breast Ca was expected to have a good prognosis.

Table 3 shows the highest values of Tg measured over the entire clinical course of thyroid Ca. The Tg levels  $>10,000$  ng/mL, detected in 9 (32%) cases of follicular Ca and 2 (50%) of undifferentiated Ca, were judged to reflect metastatic cancer activation. In addition, Tg levels of 4,000–10,000 ng/mL were observed in 7 (25%) cases of follicular Ca and 1 (25%) of undifferentiated Ca. In contrast, the cases of papillary Ca rarely showed such high Tg secretion. Most cases of papillary Ca-196 (88%) recorded maximum Tg levels of  $<500$  ng/mL throughout the entire clinical course, and 24 (11%) had maximum Tg levels of 500– $<2,000$

**Table 2.** Seven patients showing both thyroid cancer (papillary carcinoma) and breast cancer (ductal carcinoma).

Case No	Tg (ng/mL)	Anti-Tg Ab (U/mL)	Breast cancer		
			Time of mastectomy <sup>a</sup> (before/after)	CA15-3 <sup>b</sup> (U/mL)	BCA225 <sup>b</sup> (U/mL)
1	8	NT	Before	NT	110
2	NT	$<0.3$	Before	10	53
3	5	$<0.3$	Before	15	98
4	24	2.9	After	7	54
5	4	7.3	After	6	35
6	NT	NT	Before	11	78
7	22	NT	After	10	42

Tg: Serum thyroglobulin, anti-Tg AB: Antithyroglobulin antibody, NT: Not tested

<sup>a</sup>Mastectomy before or after thyroidectomy for thyroid cancer, <sup>b</sup>Pre-mastectomy data

**Table 3.** The highest serum levels of thyroglobulin (Tg) according to the histopathological type of thyroid cancer (Ca).

Pathological type	Total (n) <sup>a</sup>	Tg (ng/mL)				
		<500 (n) (%)	500–<2000 (n) (%)	2000–<4000 (n) (%)	4000–10000 (n) (%)	>10000 (n) (%)
Papillary	224	196 <sup>b</sup> (88)	24 <sup>c</sup> (11)	4 (2)	0 (0)	0 (0)
Follicular	28	3 (11)	5 (18)	4 (14)	7 (25)	9 (32)
Undifferentiated	4	0 (0)	1 (25)	0 (0)	1 (25)	2 (50)
Medullary	2	2 (100)	0 (0)	0 (0)	0 (0)	0 (0)

Tg: Thyroglobulin, anti-Tg Ab: Antithyroglobulin antibody

<sup>a</sup>Patient number<sup>b</sup>Eight cases had a serum anti-Tg Ab level of  $\geq 100$  U/mL<sup>c</sup>Two cases had a serum anti-Tg Ab level of  $\geq 100$  U/mL

ng/mL. Among 108 patients with papillary Ca in whom anti-Tg Ab was measured, and who had a maximum Tg of <500 ng/mL, 17 (16%), 6 (6%), and 8 (7%) had anti-Tg Ab levels of 1–10 U/mL, 10–100 U/mL, and  $\geq 100$  U/mL, respectively. Two cases with anti-Tg Ab values of 1–10 U/mL and  $\geq 100$  U/mL, were not measured for Tg, but were classified in the Tg range of <500 ng/mL. One (7%) case and 2 (13%) cases of these 15 cases of papillary Ca with Tg 500–<2,000 ng/mL showed anti-Tg Ab levels of 15.5 and  $\geq 100$  U/mL, respectively. Among 10 cases with anti-Tg Ab of  $\geq 100$  U/mL, 5 (50%) were male. These 10 cases of papillary Ca with anti-Tg Ab levels of  $\geq 100$  U/mL were judged to be accompanied by chronic thyroiditis. Two cases of papillary Ca with Tg levels of 1,960 ng/mL and 561 ng/mL, respectively, showed continuously high anti-Tg Ab levels, of >100 U/mL. The first, with Tg 1,960 ng/mL showed CLN metastases of papillary Ca at thyroidectomy. The other, with Tg 561 ng/mL showed accumulations of <sup>131</sup>I in the lung and lower cervical region, thought to be due to multiple lung metastases, which disappeared after the 7th IBRT of <sup>131</sup>I. In 15 cases of follicular Ca with measurements for anti-Tg Ab, only 1 case with bilateral breast Ca had anti-Tg Ab 17 U/mL at the onset, and the other 14 cases had anti-Tg Ab  $\leq 0.3$  U/mL. In all 4 cases of undifferentiated Ca anti-Tg Ab was  $\leq 0.3$  U/mL. It was concluded that high anti-Tg Ab titers were detected in papillary thyroid Ca, but not in follicular or undifferentiated thyroid Ca and that only papillary Ca had the possibility to produce autoimmune reactions. Apart from 3 cases with no definitive microscopic CLN results. Among the 24 cases of papillary Ca with Tg in the range of 500–<2,000 ng/mL, 19 were confirmed to have microscopic CLN metastasis at thyroidectomy. Two cases with Tg 1,671 and 1740 ng/mL, respectively, in which no CLN metastasis was detected at thyroidectomy, developed CLN metastasis later, although they did not show <sup>131</sup>I accumulations on <sup>131</sup>I whole-body scan. Of the 5 cases with no CLN metastasis detected initially, with Tg values of 500–<2,000 ng/mL at

thyroidectomy, one, with Tg 673 ng/mL was found later to have multiple metastases to CLN, brain, and liver. Another of the 5, with Tg 561 ng/mL had multiple lung metastases, and the last one of the 5, with Tg 722 ng/mL, showed continuously raised Tg ( $\leq 700$  ng/mL) after thyroidectomy, but no imaging evidence of metastasis. All 5 cases of papillary Ca with Tg in the range 2,000–<4,000 ng/mL must have microscopic CLN metastases. It is probable that CLN metastases present in all the 24 cases of papillary Ca at the time of diagnosis. Based on the results shown in tables 1 and 3, radical removal of CLN was strongly suggested at thyroidectomy in all the cases with thyroid Ca.

Table 4 shows the correlation between high Tg and high grade malignancy in the 4 patients with undifferentiated thyroid Ca. Case No 1 was admitted at the age of 60 years with a very high level of Tg (91,450 ng/mL). One year and 7 months post-thyroidectomy, his Tg levels began to increase rapidly, at which time multiple metastases to bone, soft tissues near the bone, and lung were observed. At that time, osteolytic tumors were recognized in the left costal and right scapular regions, and in the thoracic and lumbar vertebrae. The tumor in the 8th thoracic vertebra was the largest and associated with bone fracture.

**Table 4.** Correlation between high levels of serum thyroglobulin (Tg) values and a high degree of malignancy in 4 patients with undifferentiated thyroid cancer.

Case No	Tg (ng/mL)	Metastasis		<sup>131</sup> I ablation	Clinical state
		Soft tissue <sup>a</sup>	Lung	Effectiveness	
1	712,940	(+)	(+)	(–)	Progressive
2	49,831	(+)	(+)	(–)	Progressive
3	6,342	(+)	(+)	(+)	Improved
4 <sup>b</sup>	730	(–)	(+)	(+)	Improved

<sup>a</sup>Near to bone<sup>b</sup>Papillary carcinoma with undifferentiated components.

Case No 2, a female aged 62 years, was also admitted a very high level of Tg (35,811 ng/mL), and multiple lung metastases, metastases to around the cervical vertebrae and the right hilar lymph nodes were recognized after the first <sup>131</sup>I ablation. She showed weak accumulation of <sup>131</sup>I in the lung, the hilar and mediastinal lymph nodes and the left cerebrum after the 2nd <sup>131</sup>I ablation. Cases No 1, and 2 showed continuously very high levels of Tg, the highest being 712,940 ng/mL in No 1 and 54,998 ng/mL in No 2. Cancer remnants proliferated in both the cases post-IBRT with <sup>131</sup>I, for which IBRT was ineffective. Case No 3 was a man aged 69 years at admission with signs of tumor, including weakness and discomfort in his left leg; a tumor of the 5th thoracic vertebra was shown later to be a metastasis of follicular thyroid Ca. The metastatic tumor was cytokeratin 7 (CK7) (+), CK20 (+), thyroglobulin (+), and thyroid transcription factor-1 (TTF-1) (+). After subtotal resection of the 5th thoracic vertebra tumor, Tg levels decreased from 6,342 ng/mL to about 1,000 ng/mL, and 6.5 months later, Tg level had decreased further from 1,000 to 300 ng/mL after total thyroidectomy, with the diagnosis of poorly differentiated Ca. One year post-resection, the 5th thoracic vertebra tumor was further removed and Tg decreased to normal level. This patient had a past history of pulmonary embolism and emphysema, but metastases to lung were not found on several examinations during his clinical course. He was effectively treated twice with IBRT of <sup>131</sup>I after the 2nd of which <sup>131</sup>I accumulation disappeared, with normal Tg. Case No 4 was a female aged 19 years with Tg 485 ng/mL and multiple lung metastases on admission. Total thyroidectomy was performed and the first IBRT of <sup>131</sup>I was started. Histopathological examination showed papillary thyroid Ca with a poorly differentiated component. Whole-body scintigraphy after the first IBRT showed <sup>131</sup>I accumulation in a lymph node (LN) of the supraclavicular fossa and diffuse <sup>131</sup>I accumulation in her lung. Subsequently, Tg decreased to normal from 730 ng/

mL. She had anti-Tg Ab of ≤0.3 U/mL. When the second IBRT of <sup>131</sup>I was started 8 months after the first, whole-body scintigraphy showed no change and Tg, which had risen to 730 ng/mL, again decreased to normal, but rose to 812 ng/mL 6 months later. <sup>131</sup>I whole-body scan showed weak accumulation of <sup>131</sup>I in both lungs after the 3rd <sup>131</sup>I ablation. While in case No 3, Tg decreased continuously to <0.8 ng/mL after the 2nd <sup>131</sup>I ablation, in case No 4 Tg decreased once to 74 ng/mL. It was therefore judged that case No 3 and case No 4, both with relatively low initial Tg, showed effective reactions to <sup>131</sup>I ablation, whereas the cases with Tg >10,000 ng/mL, <sup>131</sup>I ablation did not work effectively. Surgical resection of soft tissue and bone metastases effectively improved the clinical findings, as shown by the down-regulated Tg.

Table 5 shows the relationship between high levels of Tg and signs of high malignancy in 28 patients with follicular Ca. The patients are classified into 5 subclasses according to their highest level of Tg. The 9 cases with Tg >10,000 ng/mL had advanced metastases to soft tissues, bone and lung, in contrast with the 19 cases with Tg <10,000 ng/mL, and especially with the 8 cases with Tg <2,000 ng/mL, in which lung metastasis was more common. Figures 1 to 3 indicate the continuous changes in the level of Tg values observed in 3 of the patients with follicular Ca, none of whom died in the study hospital. One male with follicular Ca, whose Tg was in the range of 2,000–<4,000 ng/mL in table 5, had undergone left thyroid lobectomy for papillary Ca at the age of 78 years in 1988. In 1992 he underwent total thyroidectomy for follicular Ca. His diagnosis of thyroid cancer thus changed from papillary to follicular Ca. Lung metastases of follicular Ca removed in January 2004 showed Tg (+), TTF-1 (+), and vimentin (–) by immunochemical staining. He had undergone a first <sup>131</sup>I IBRT (100 mCi) in 1992, and with the suspicion of in December, 2003, the 2nd <sup>131</sup>I ablation of 100 mCi was started, following which, in February, 2004, <sup>131</sup>I accumulation was indicated from

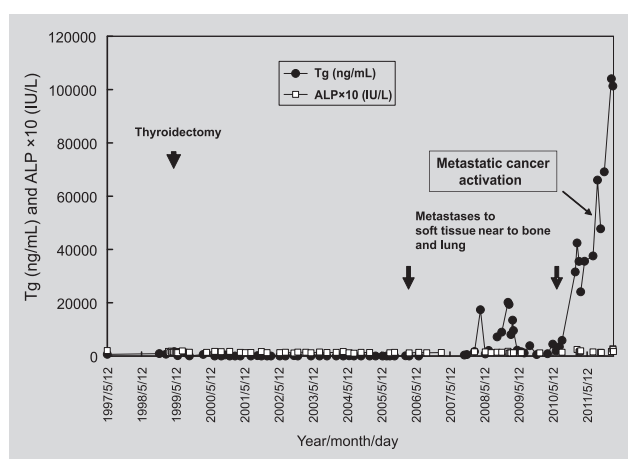
**Table 5.** Correlation between high levels of serum thyroglobulin (Tg) and a high degree of malignancy in 28 patients with follicular thyroid carcinoma.

Tg (ng/mL)	Total patients (n)	Metastasis		Metastatic cancer activation <sup>a</sup>	
		Soft tissue <sup>b</sup> (%) (n) <sup>d</sup>	Lung (%) (n) <sup>d</sup>	Patient (%) (n) <sup>d</sup>	Followed period <sup>c</sup> (Year)
>10,000	9	78 (7/9)	89 (8/9)	100 (9/9)	0.1–28.7
4,000–10,000	7	29 (2/7)	29 (2/7)	43 (3/7)	0.3–8.9
2,000–<4,000	4	50 (2/4)	50 (2/4)	0 (0/4)	–
500–<2,000	5	20 (1/5)	80 (4/5)	0 (0/5)	–
<500	3	33 (1/3)	67 (2/3)	0 (0/3)	–

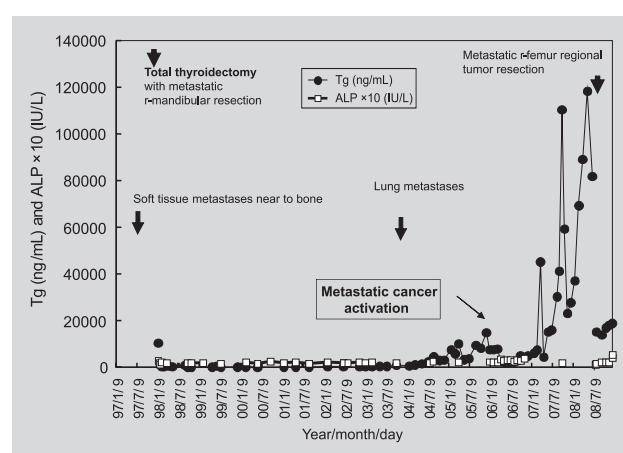
<sup>a</sup>See figures 1–3, <sup>b</sup>Near to bone, <sup>c</sup>From cancer diagnosis to the end of recognition, or February, 2012, <sup>d</sup>Positive patient number to total patient number

the lower cervical to the upper thoracic vertebrae and in the left lung. The lung metastases with  $^{131}\text{I}$  accumulation were worse even after the 4th IBRT in 2005. This man thus had a tendency for metastatic cancer activation 13 years after total thyroidectomy. A female patient with follicular Ca, who had undergone resection of metastatic tumor at the age of 53 years, had Tg 5,700, and was sub-classified into the Tg range 4,000–10,000 ng/mL. She had been diagnosed with follicular Ca in 1998, at which time she was already in the preliminary stage of cancer cell activation, with metastatic tumor ranging from the chest wall to the costal bone. Another metastatic tumor caused right femur fracture in 2000. After resection of metastatic tumors involving in bone, Tg decreased to about 500 ng/mL, indicating a beneficial effect, even though the metastases had advanced rapidly. The 3 cases shown in figures 1, 2, and 3 had metastatic cancer activation at an advanced stage and were sub-classified into the Tg range of >10,000 ng/mL. In the female in figure 1, thyroidectomy was performed for follicular Ca in 1999 when she was 68 years old. In 2006, after the 8th IBRT of  $^{131}\text{I}$ , she showed  $^{131}\text{I}$  accumulation in the upper arm and sacral region on the left side. In 2008, Tg began to increase gradually, reaching 104,027 ng/mL in 2012. In 2010, chest X-ray showed multiple lung metastases and the 12th IBRT of  $^{131}\text{I}$  was applied. In this patient the serum levels of alkaline phosphatase (ALP) remained below 200 IU/L, apart from 247, 274, and 239 IU/L recorded after 2011. As the ALP was in the normal range (117–356 IU/L), it appeared that osteolysis caused directly by tumor infiltration did not cause elevation of ALP. The case in figure 2 was that of a 54 year-old female,

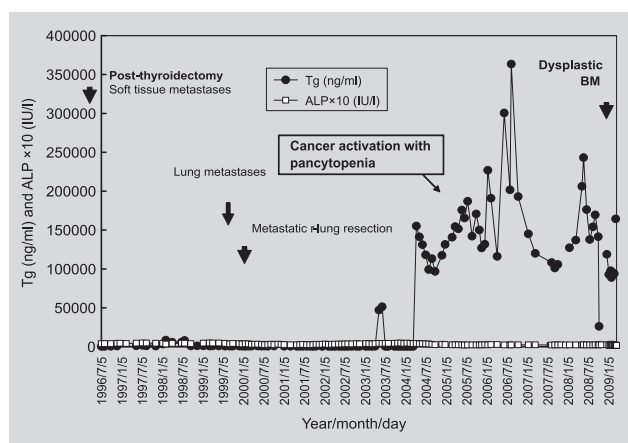
admitted with a fracture of the right mandible in 1998. Multiple soft tissue metastases near to bone had already been recognized in 1998 before the diagnosis of follicular thyroid Ca was established. Lysis of the 10th left costal bone was detected on chest CT. After total thyroidectomy together with resection of the right mandibular metastasis, the first IBRT of  $^{131}\text{I}$  was started. In 2004, lung metastases became apparent, which had worsened in 2008. In May 2008, liver metastasis was detected and in September 2008 a right femoral metastasis which had been subjected to external beam radiotherapy (EBRT) of 51 Gy 26 times was removed, and identified. Histological examination showed that 50% of the femoral tumor was necrotic, but the other 50% was composed of viable follicular Ca cells stained positively for Tg Ab. Atypical follicular epithelial cells were identified between muscle and bone, accompanied by fibrous interstitial cell proliferation. Soft tissue metastasis had occurred through venous channels first to soft tissues and then invading bone, causing fracture. In October 2008 she developed raised white blood cell (WBC) count with peripheral lymphopenia. Although this case showed very high levels of Tg, abnormally high ALP values of 427, 416, and 524 IU/L were measured only in December 2008, which was the last time of being followed in our hospital. The case in figure 3 was that of a female aged 79 years when right lung metastases of follicular thyroid Ca were removed in February 2000. The definitive diagnosis of follicular thyroid Ca had been made in 1982, although she already had soft tissue metastases near to bone in 1980. One small lung metastasis was confirmed in 1999, which was observed to be enlarged in 2004, together with



**Figure 1.** Serial serum levels of thyroglobulin (Tg) and alkaline phosphatase (ALP) in a female with follicular thyroid carcinoma (1999 onset). Remarkably elevated Tg levels indicated metastatic cancer activation. Serum ALP elevation was not observed in spite of multiple soft tissue metastases near to bone.



**Figure 2.** Serial serum levels of thyroglobulin (Tg) and alkaline phosphatase (ALP) in a female with follicular thyroid carcinoma (1980 onset). She began to show metastatic tumor activation with very high levels of Tg 24 years after diagnosis and bone marrow dysplasia with peripheral pancytopenia 28.5 years after diagnosis.



**Figure 3.** Serial serum levels of thyroglobulin (Tg) and alkaline phosphatase (ALP) in a female with follicular thyroid carcinoma (1998 onset). She had early multiple soft tissue metastases near to the bone. Very high levels of Tg were down-regulated after a right femoral regional metastasis was removed.

very small nodules. Lower thoracic vertebrae, 5th lumbar vertebra, ribs, xiphoid process, mandible and right femur were areas with accumulated <sup>131</sup>I in 2004, and uterine metastasis was confirmed in 2006. In April 2004, Tg levels began to increase to higher than 100,000 ng/mL when metastatic cancer activation was observed. In October 2008 serum adenosine deaminase (ADA) was 12.8 U/L (normal range: 5.0–20.0 U/L). In January 2009 bone marrow (BM) aspiration revealed macrophage proliferation of p53 (+++) and CD163 (+), with numerous mature lymphocytes and plasma cells. The numbers of CD34 (+) cells were small. Micromegakaryocytes of CD42b (+) and CD61 (+) were detected sporadically. Dysplastic BM was induced in this patient with follicular thyroid Ca 28.5 years after the first diagnosis. From October 2008 peripheral pancytopenia became progressively severe, and in March 2009 the hemoglobin was 7.9 g/dL, WBC 3,300/μL and platelet count 0.4×10<sup>4</sup>/μL, with a peripheral lymphocytopenia of 330/μL. At the same time, fluid collected in the thoracic cavity.

**DISCUSSION**

In this study, it was shown that thyroid cancers metastasized to CLN, lung, soft tissue near to bone, and then to the bone itself, through lymphatic vessels and venous channels. The rate of identified microscopic CLN metastasis in follicular Ca (75%) was lower than that in papillary Ca (86%). Even in papillary Ca with normal Tg the rate of microscopic CLN metastasis was 84%. Follicular Ca had a high rate of metastasis to soft tissues near the bone, and a higher rate of lung metastasis than papillary Ca. Metastasis

to the mandible was recognized as the presenting sign of follicular Ca in this study. Soft tissue metastasis near to the bone sometimes encroached on bone and muscle. The infiltration of thoracic vertebrae by metastatic thyroid cancer cells as the first clinical sign gave rise to diagnostic difficulties in a case with undifferentiated Ca in this study. The contradictory findings of CLN metastases between papillary Ca and follicular Ca were explained as follows: In papillary Ca, lymphatic vessel metastases occurred first, but in follicular Ca, venous channel metastases occurred at an early stage, together with lymphatic vessel metastases. Actual CLN metastases in follicular Ca should be higher than 86% in papillary Ca. High expression of vascular endothelial growth factor-C (VEGF-C) and lymphatic vessel density (LVD), using D2-40, was evaluated as a lymph node metastasis marker in papillary thyroid Ca.<sup>5</sup> Dominant tumor nodules of Hürthle cell carcinoma (HCC), which is an aggressive variant of follicular thyroid Ca, have been reported in the soft tissues, 59% of which have been detected in elastic staining veins.<sup>6</sup> It has also been reported that neuropilin-2 (Nrp2), which is a co-receptor for VEGF-D expressed on endothelial cells, plays an important role in the metastases of papillary thyroid Ca and in the promotion of cancer cell migration.<sup>7</sup> VEGF-D, which is regulated by thyroid cancer Nrp2 and binds the tyrosine kinase VEGF receptors 2 and 3, is thought to have promoted lymphoangiogenesis, resulting in tumor lymphatic and venous metastases. VEGF-D activation in the metastases of papillary thyroid Ca was also shown by the up-regulated pathway of signal transducers and activators of transcription 3 (STAT3) and its phosphorylated and activated form, pSTAT3.<sup>8</sup> It was recently reported that VEGF-D has a potential role in progestin-induced breakthrough bleeding.<sup>9</sup> As soft tissue metastases near to bone were observed mainly in elderly females with follicular Ca, as shown in figures 1, 2, and 3, female hormone-induced breakthrough bleeding in dilated thin-walled blood and lymphatic vessels might be accelerated by VEGF-D activation in elderly females with follicular Ca. Surgical tumor curettage of soft tissue metastases near to bone or encroaching into bone was an effective form of treatment observed to improve clinical signs and prolong survival. These lesions were caused mainly by venous metastases, in contrast with lung metastases which are thought to be due to lymphatic vessel spread.

Some cases were admitted with multiple lung metastases before the diagnosis of papillary thyroid Ca. As metastases had already occurred in 80–100% of cases by the time of thyroid Ca diagnosis, effective treatment was mandatory post-thyroidectomy. <sup>131</sup>I ablation RI therapy for remnant ablation was effective for metastases to lung and superior to lung lobectomy in thyroid Ca. After IBRT of <sup>131</sup>I, whole-

body scan easily investigated the positive spots of thyroid cancer lung metastases in terms of diagnostic benefit. IBRT of  $^{131}\text{I}$  was more effective for thyroid Ca metastases through lymphatic vessels than through venous vessels.

Based on the above data, improved RIT management for all patients with DTC was considered to include  $^{131}\text{I}$  whole-body scan of 3 to 5 mCi to identify metastases. In this series of Japanese patients it was shown that the extent of cancer metastases showing  $^{131}\text{I}$  uptake had significant prognostic value ( $p < 0.001$ ), and delaying initial  $^{131}\text{I}$  RIT until more than 180 days after total thyroidectomy resulted in poor survival in DTC ( $p = 0.005$ ).<sup>10</sup> The risk of death in patients treated by initial RIT more than 180 days post-thyroidectomy was 4.22 times higher than that in the patients treated within 180 days. RI remnant ablation at post-thyroidectomy is recommended for all cases of DTC with microscopic CLN metastases. When the patients have a low risk of metastasis, a minidose outpatient ablation protocol should be employed. It was shown that surgery alone ablated thyroid Ca at a rate of about 10% of patients.<sup>11</sup> In the some report, it was described that at mini dose of 740 MBq/20 mCi with rhTSH, which was basically the same RIT as stated below, a final ablation success rate of 92% was achieved in the patients with stimulated serum Tg  $< 10$  ng/mL at minidose 1. In Japanese, low  $^{131}\text{I}$  administration (500 MBq/13.5 mCi) should be repeated twice at 6 month intervals with rhTSH stimulation (rhTSH is administered for 2 consecutive days 24 hours before the  $^{131}\text{I}$  administration). When remnants are found, radioactive remnant ablation using  $^{131}\text{I}$  of 100 mCi to 200 mCi should be started as usual. In all cases with DTC, the first IBRT of  $^{131}\text{I}$  must be planned within 1–2 months post-thyroidectomy.

The prognostic value of serum Tg was evaluated in thyroid cancers. In a strict sense, low or normal levels of serum Tg did not rule out microscopic CLN metastases of papillary Ca, but high Tg levels helped in the diagnosis of follicular and undifferentiated Ca. A Tg level of more than 500 ng/mL post-thyroidectomy indicated a poor prognosis. Positive correlation was observed between high Tg and a high degree of malignancy. Serum Tg has been shown to be one of the most significant markers of persistent/recurrent thyroid Ca.<sup>12</sup> In the case of difficulty in confirming the persistence/recurrence of thyroid Ca on  $^{131}\text{I}$  whole-body scan, the serum Tg level helped the evaluation substantially in this study. As metastatic follicular and undifferentiated Ca secretes Tg actively, levels of Tg higher than normal could clearly indicate the persistence/recurrence of the cancers post-thyroidectomy. Among 715 patients with DTC, 32 (4.5%) patients treated with RIT showed recurrence during the median follow-up period of 6.2 years.<sup>12</sup> Initial Tg

measurements, for which the Tg Access kit with functional sensitivity of 0.11 ng/mL was used, enabled prediction of long-term recurrence with excellent specificity. When Tg measured 3 months after ablation was less than 0.27 ng/mL during levothyroxine (LT4) treatment, Tg measurement at 9–12 months after stimulation by either TH withdrawal (THW) or rTSH could be avoided. It was absolutely necessary to measure serum Tg to recognize metastasis, together with  $^{131}\text{I}$  whole-body scan.

It has been reported that women with benign breast disease (BBD) have a significantly higher risk of thyroid Ca than women without.<sup>13</sup> In this study, 12 women with papillary Ca and 1 with follicular Ca showed bilateral breast cancer. It thus appears that an abnormal gene of thyroid Ca must be related to an abnormal breast cancer gene. Germline variants in succinate dehydrogenase (SDHx) genes, mitochondrial respiratory enzyme genes, were suggested to be predisposing and modifier genes of breast and thyroid cancer risks in CS and Cowden-like syndrome (CS-like) via flavin adenine dinucleotide (FAD)/nicotinamide adenine dinucleotide (NAD)-dependent destabilization of p53.<sup>14</sup> Variant SDHx in CS/CS-like is associated with hyperactivated hypoxia-inducible factor (HIF)1 $\alpha$ , p53 loss and abnormality in the signaling pathway of phosphatase and tensin homolog (PTEN), which caused tumorigenesis. It was also reported that, of 2,723 CS/CS-like patients, 664 (24%) had thyroid Ca, in which standardized incidence rates were 72 for pathogenic PTEN mutations, 63 for SDHx variants, and 45 for epimutations of tumor suppressor gene KLLN (encoding KILLIN), which lies upstream of PTEN.<sup>15</sup> In CS/CS-like patients, follicular thyroid Ca was most often caused by PTEN mutations, and papillary Ca was mostly from SDHx and KLLN alterations. In this study, bilateral breast Ca was suggested to be triggered more often by SDHx variants than by PTEN mutations, as papillary thyroid Ca was found in 92% (12/13) of these cases.

VEGF-induced aggressive cancer metastases are thought to be triggered in a hypoxic environment producing elevated reactive oxygen species (ROS). DNA damage, genetic instability, and gene mutations on the basis of ROS may be responsible for the changeable malignancy sometimes observed in thyroid Ca. A case of follicular Ca with peripheral pancytopenia had p53- and CD163-positive macrophage proliferation in the BM 28.5 years after the onset of the follicular Ca, with very high Tg. In this patient, pleural effusion was observed with peripheral lymphopenia. Recently, increased infiltration of M1 macrophages expressing nitric oxide synthase 2 (NOS2), accompanied by M2 (CD163) macrophages, was reported to be correlated with a better prognosis in patients with colorectal cancer



(CRC).<sup>16</sup> The BM CD163-positive M2 macrophages of this patient, which expressed p53 actively, might have played a tumor-preventing role in the tumorigenesis of thyroid

Ca, because the follicular Ca cells appeared to have caused p53 loss with secondary disturbance in the PTEN gene.

## ΠΕΡΙΛΗΨΗ

### Κλινικά ευρήματα καρκίνου του θυρεοειδούς σε 288 Ιάπωνες: Πρώιμες μεταστάσεις οστών και μαλακών μορίων με αύξηση της θυρεοσφαιρίνης ορού σε θυλακιώδη και αδιαφοροποίητο τύπο καρκίνου

T. NAKATSUJI

*Department of Transfusion Cell Therapy, Hamamatsu University School of Medicine, Hamamatsu, Ιαπωνία*

*Αρχεία Ελληνικής Ιατρικής 2013, 30(3):299–308*

**ΣΚΟΠΟΣ** Αναλύθηκαν 288 (44%) μικροσκοπικοί καρκίνοι του θυρεοειδούς σε 661 Ιάπωνες με όζους του θυρεοειδούς. **ΥΛΙΚΟ-ΜΕΘΟΔΟΣ ΚΑΙ ΑΠΟΤΕΛΕΣΜΑΤΑ** Οι περιπτώσεις καρκίνου του θυρεοειδούς περιελάμβαναν θηλώδες καρκίνωμα σε 249 (86,5%), θυλακιώδες καρκίνωμα σε 28 (9,7%), αδιαφοροποίητο καρκίνωμα σε 4 (1,4%) και μυελοειδές καρκίνωμα σε 7 άτομα (2,4%). Ακόμη και σε 104 περιπτώσεις με θηλώδες καρκίνωμα, με φυσιολογικά επίπεδα θυρεοσφαιρίνης (Tg) (4–78 ng/mL), κατά τη θυρεοειδεκτομή, σε ποσοστό 84% ανευρέθηκαν μικροσκοπικές μεταστάσεις στους τραχηλικούς λεμφαδένες. Και οι 28 περιπτώσεις με θυλακιώδες καρκίνωμα και τιμές Tg που ανέρχονταν σε >500 ng/mL εκδήλωσαν μεταστάσεις εκτός του θυρεοειδούς. Αντίσωμα αντι-Tg  $\geq 100$  U/mL ανιχνεύτηκε μόνο σε 10 περιπτώσεις με θυλακιώδες καρκίνωμα. Έκκριση μεγάλων ποσοτήτων Tg (>10.000 ng/mL) από μεταστάσεις σε μαλακά μόρια, οστά ή πνεύμονα ανιχνεύτηκαν σε 9 (32%) περιπτώσεις με θυλακιώδη και σε 2 περιστατικά (50%) με αδιαφοροποίητο καρκίνο. Τιμές Tg που κυμαίνονταν από 4.000–10.000 ng/mL παρατηρήθηκαν σε 7 (25%) περιπτώσεις με θυλακιώδες καρκίνωμα και σε 1 (25%) περίπτωση αδιαφοροποίητου καρκινώματος. Μια ηλικιωμένη γυναίκα με θυλακιώδες νεόπλασμα, από την οποία προέκυψαν τιμές Tg >10.000 ng/mL, ανέπτυξε μυελική δυσπλασία με αύξηση των p53- και CD163-θετικών μακροφάγων και περιφερική πανκυτταροπενία 28,5 έτη μετά από την εμφάνιση του καρκίνου του θυρεοειδούς. Οι περιπτώσεις με θυλακιώδες καρκίνωμα και με σχετικά χαμηλές τιμές Tg <2.000 ng/mL εμφανίζουν συχνότερα μεταστάσεις στον πνεύμονα. Εκτός από τον καρκίνο του θυρεοειδούς, 12 περιστατικά (4,8%) με θηλώδες και 1 (3,6%) με θυλακιώδες καρκίνωμα, για τα οποία υπήρχε υποψία συνδρόμου Cowden, συνοδεύονταν από διπλό καρκίνο του μαστού και καλή πρόγνωση, εκτός δύο περιπτώσεων με υψηλές τιμές Tg (673 και 704 ng/mL). **ΣΥΜΠΕΡΑΣΜΑΤΑ** Οι καρκίνοι του θυρεοειδούς εμφανίζουν πολύ πρώιμες μεταστάσεις, αλλά έχουν μακρά επιβίωση.

**Λέξεις ευρητηρίου:** Ενεργοποίηση μεταστατικού καρκίνου, Θυρεοσφαιρίνη ορού, Καρκίνος θυρεοειδούς, Καρκίνος μαστού, Μετάσταση οστών και μαλακών μορίων, Μετάσταση τραχηλικών λεμφαδένων

## References

- WEINRIB SL, LANE WS, RAPPAPORT JM. Successful management of differentiated thyroid cancer in a community-based endocrine practice. *Endocr Pract* 2012, 18:170–178
- PAGANO L, CAPUTO M, SAMÀ MT, GARBACCIOV, ZAVATTARO M, MAURI MG ET AL. Clinical-pathological changes in differentiated thyroid cancer (DTC) over time (1997–2010): Data from the University Hospital “Maggiore della Carita” in Novara. *Endocrine* 2012, 42:382–390
- TAN MH, MESTER J, PETERSON C, YANG Y, CHEN JL, RYBICKI LA ET AL. A clinical scoring system for selection of patients for PTEN mutation testing is proposed on the basis of a prospective study of 3042 probands. *Am J Hum Genet* 2011, 88:42–56
- MASMOUDI A, CHERMI ZM, MARREKCHI S, RAIDA BS, BOUDAYA S, MSEDDI M ET AL. Cowden syndrome. *J Dermatol Case Rep* 2011, 15:8–13
- LEE SH, LEE SJ, JIN SM, LEE NH, KIM DH, CHAE SW ET AL. Relationships between lymph node metastasis and expression of CD31, D2-40, and vascular endothelial growth factors A and C in papillary thyroid cancer. *Clin Exp Otorhinolaryngol* 2012, 5:150–155
- BISHOP JA, WU G, TUFANO RP, WESTRA WH. Histological patterns of locoregional recurrence in Hürthle cell carcinoma of the thyroid gland. *Thyroid* 2012, 22:690–694
- YASUOKA H, KODAMA R, HIROKAWA M, TAKAMURA Y, MIYAUCHI A, INAGAKI M ET AL. Neuropilin-2 expression in papillary thyroid carcinoma: Correlation with VEGF-D expression, lymph node metastasis, and VEGF-D-induced aggressive cancer cell phenotype. *J Clin Endocrinol Metab* 2011, 96:E1857–E1861

8. ZHANG J, GILL A, ATMORE B, JOHNS A, DELBRIDGE L, LAI R ET AL. Up-regulation of the signal transducers and activators of transcription 3 (STAT3) pathway in lymphatic metastases of papillary thyroid cancer. *Int J Clin Exp Pathol* 2011, 4:356–362
9. DONOGHUE JF, MCGAVIGAN CJ, LEDERMAN FL, CANN LM, FU L, DIMITRIADIS E ET AL. Dilated thin-walled blood and lymphatic vessels in human endometrium: A potential role for VEGF-D in progesterin-induced break-through bleeding. *PLoS One* 2012, 7:e30916
10. HIGASHI T, NISHII R, YAMADA S, NAKAMOTO Y, ISHIZU K, KAWASE S ET AL. Delayed initial radioactive iodine therapy resulted in poor survival in patients with metastatic differentiated thyroid carcinoma: A retrospective statistical analysis of 198 cases. *J Nucl Med* 2011, 52:683–689
11. CLERC J, BIENVENU-PERRARD M, DE MALLERAY CP, DAGOUSSET F, DELBOT T, DREYFUSS M ET AL. Outpatient thyroid remnant ablation using repeated low 131-iodine activities (740 MBq/20 mCi $\times$ 2) in patients with low-risk differentiated thyroid cancer. *J Clin Endocrinol Metab* 2012, 97:871–880
12. BRASSARD M, BORGET I, EDET-SANSON A, GIRAUDET AL, MUNDLER O, TOUBEAU M ET AL. Long-term follow-up of patients with papillary and follicular thyroid cancer: A prospective study on 715 patients. *J Clin Endocrinol Metab* 2011, 96:1352–1359
13. SCHONFELD SJ, RON E, KITAHARA CM, BRENNER A, PARK Y, SIGURDSON AJ ET AL. Hormonal and reproductive factors and risk of postmenopausal thyroid cancer in the NIH-AARP Diet and Health Study. *Cancer Epidemiol* 2011, 35:e85–e90
14. NI Y, HE X, CHEN J, MOLINE J, MESTER J, ORLOFF MS ET AL. Germline SDHx variants modify breast and thyroid cancer risks in Cowden and Cowden-like syndrome via FAD/NAD-dependant destabilization of p53. *Hum Mol Genet* 2012, 21:300–310
15. NGEOW J, MESTER J, RYBICKI LA, NI Y, MILAS M, ENG C. Incidence and clinical characteristics of thyroid cancer in prospective series of individuals with Cowden and Cowden-like syndrome characterized by germline PTEN, SDH, or KLLN alterations. *J Clin Endocrinol Metab* 2011, 96:E2063–E2071
16. EDIN S, WIKBERG ML, DAHLIN AM, RUTEGÅRD J, ÖBERG Å, OLDENBORG PA ET AL. The distribution of macrophages with a M1 or M2 phenotype in relation to prognosis and the molecular characteristics of colorectal cancer. *PLoS One* 2012, 7:e47045

*Corresponding author:*

T. Nakatsuji, Department of Transfusion Cell Therapy, Hamamatsu University School of Medicine, 1-20-1 Handayama, Higashi-ku, Hamamatsu 431-3192, Japan  
e-mail: n2c68tadako@snow.plala.or.jp

.....