

## CONTINUING MEDICAL EDUCATION ΣΥΝΕΧΙΖΟΜΕΝΗ ΙΑΤΡΙΚΗ ΕΚΠΑΙΔΕΥΣΗ

### Oral Medicine and Pathology Quiz – Case 21

A 46-year-old woman presented to our clinic with a painless swelling in the left maxilla, which had been present and progressively enlarging for approximately one year. Her medical history was significant for hypertension controlled by medication. She had been a smoker for about 25 years. Clinical examination revealed a buccal swelling of the left maxillary bone extending from the midline to the left first molar area, which was hard in consistency and non-sensitive on palpation. No lymphadenopathy was identified. Panoramic radiograph revealed an ill-defined multilocular radiolucent lesion with fine trabeculation in the left maxilla (fig. 1). On surgical exploration, perforation of the left maxillary buccal bone plate was noticed; an incisional biopsy of the lesion was performed. On gross examination, a gelatinous consistency of the biopsy specimen was apparent. Histopathologic examination showed that the lesion was composed almost exclusively of myxoid material with loosely arranged spindle and stellate cells (fig. 2). On the basis of the final microscopic diagnosis, a complete resection of the lesion was performed.

#### Comment

*Odontogenic myxoma (OM) is a rare benign but locally aggressive tumor of the jaws. It is considered to originate from the odontogenic ectomesenchyme and is classified as a mesenchymal odontogenic neoplasm. In support of an odontogenic origin, these tumors*

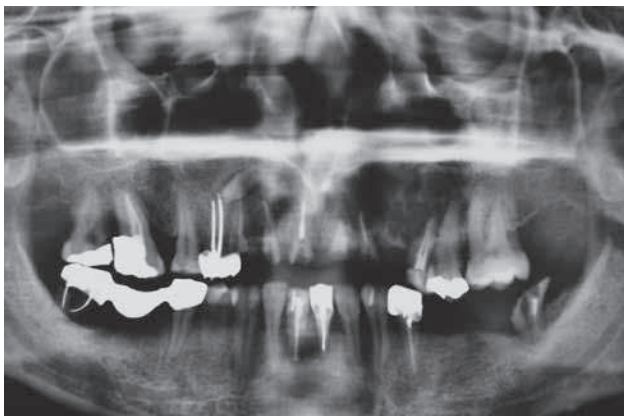

Figure 1

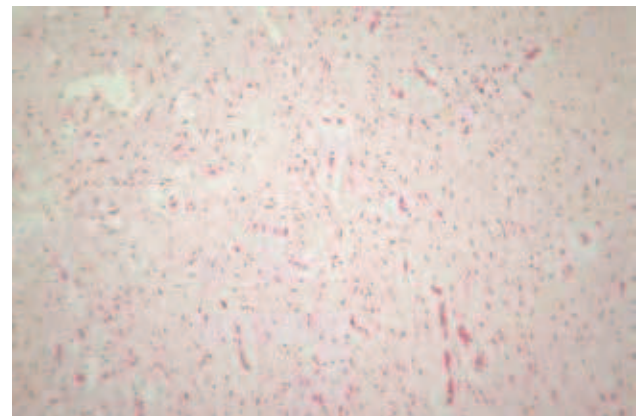


Figure 2

ARCHIVES OF HELLENIC MEDICINE 2012, 29(6):766–767  
ΑΡΧΕΙΑ ΕΛΛΗΝΙΚΗΣ ΙΑΤΡΙΚΗΣ 2012, 29(6):766–767

**N.G. Nikitakis,  
S. Titsinides,  
A. Sklavounou-Andrikopoulou**

*Department of Oral Medicine and  
Pathology, School of Dentistry, National  
and Kapodistrian University of Athens,  
Athens, Greece*

*occur in proximity to the tooth bearing parts of the jaws, are often associated with a missing or unerupted tooth and, in a minority of cases, contain odontogenic epithelium.*

*The frequency of OM varies widely from 0.5–20% of all odontogenic tumors showing differences among various parts of the world; for example, in series from Africa, OM is the second commonest odontogenic tumor following ameloblastoma. Almost any age group may be affected with the majority of tumors occurring in the second and third decades of life. A slight predilection for females has been recorded.*

*OM involves the mandible more often than the maxilla, usually localized in the molar/premolar region. It usually presents as a progressively growing lesion, which may be discovered as an incidental radiographic finding. At later stages, significant bone expansion and perforation with subsequent extension into the surrounding soft tissues might be observed. Of note, maxillary tumors often extend into the sinus. Also, tooth mobility and, less often, pain and paresthesia may be reported.*

*Radiographically, OM may appear as a unilocular or multilocular radiolucency with fine trabeculation, sometimes exhibiting a honeycomb or soap-bubble pattern. The margins are well- or ill-defined, irregular or scalloped. Other radiographic findings include cortical expansion, tooth displacement and root resorption.*

*Microscopically, OM appears as a non-encapsulated tumor, consisting of spindle shaped, stellate and or round cells in an abundant loose, myxoid stroma. Collagen fibers are very limited and scattered islands of inactive odontogenic epithelium are infrequently discerned. Microscopic differential diagnosis should include other myxoid neoplasms, as well as myxoid changes within the dental follicle or the dental papilla of a developing tooth.*

*OM is a benign neoplasm not associated with risk of malignant transformation or metastatic behavior; nonetheless, it is characterized by the potential for locally aggressive growth. The lack of a capsule and the infiltrative growth pattern are responsible for a high recurrence rate following simple curettage or enucleation. The risk of recurrence is minimized with a more extensive resection procedure, an approach particularly indicated in the maxilla due to the proximity of vital structures. Overall recurrence rate is estimated to be 25%; however, the prognosis is considered good, despite rare fatal cases due to cranial base extension. Long-term follow-up with periodical clinical and radiographic examination is mandatory.*

## References

1. KANSY K, JUERGENS P, KROL Z, PAULUSSEN M, BAUMHOER D, BRUDER E ET AL. Odontogenic myxoma: diagnostic and therapeutic challenges in paediatric and adult patients – a case series and review of the literature. *J Craniomaxillofac Surg* 2012, 40:271–276
2. SINGARAJU S, WANJARI SP, PARWANI RN. Odontogenic myxoma of the maxilla: A report of a rare case and review of the literature. *J Oral Maxillofac Pathol* 2010, 14:19–23
3. BRANNON RB. Central odontogenic fibroma, myxoma (odontogenic myxoma, fibromyxoma), and central odontogenic granular cell tumor. *Oral Maxillofac Surg Clin North Am* 2004, 16:359–374

### Corresponding author:

N.G. Nikitakis, Department of Oral Pathology and Medicine, School of Dentistry, National and Kapodistrian University of Athens, 2 Thivon street, GR-115 27 Athens, Greece, tel.: +30 210 74 61 003, fax: +30 210 7461220  
e-mail: nnikitakis1@yahoo.com