

CONTINUING MEDICAL EDUCATION ΣΥΝΕΧΙΖΟΜΕΝΗ ΙΑΤΡΙΚΗ ΕΚΠΑΙΔΕΥΣΗ

Oral Medicine and Pathology Quiz – Case 17

A 48 years old female was referred to our clinic for investigation of an asymptomatic white plaque of unknown duration on the right buccal mucosa. The patient reported a chronic cheek biting habit and was a heavy smoker. Her medical history was significant only for allergic rhinitis, which was managed by oral antihistamine medication. On clinical examination, a 1.0×0.5cm white plaque with a radiating periphery was noticed on the right posterior buccal mucosa in contact with a buccal amalgam filling on the adjacent second mandibular molar (fig. 1). A similarly looking white plaque was seen on the right lateral border of the tongue, again in contact with a lingually extended amalgam filling. A biopsy of the buccal mucosal lesion was performed and revealed degeneration of the basal epithelial cell layer, intense band-like lymphocytic infiltrate of the underlying connective tissue as well as deep perivascular inflammatory infiltrates (fig. 2). On the basis of the diagnosis, the patient was advised to remove the amalgam fillings in the area. Three months postoperatively, no oral mucosal lesions were present.

Comment

Lichenoid contact stomatitis to a restorative material is a relatively uncommon condition where the mucosa adjacent to the restoration exhibits lesions similar to oral lichen planus. Any

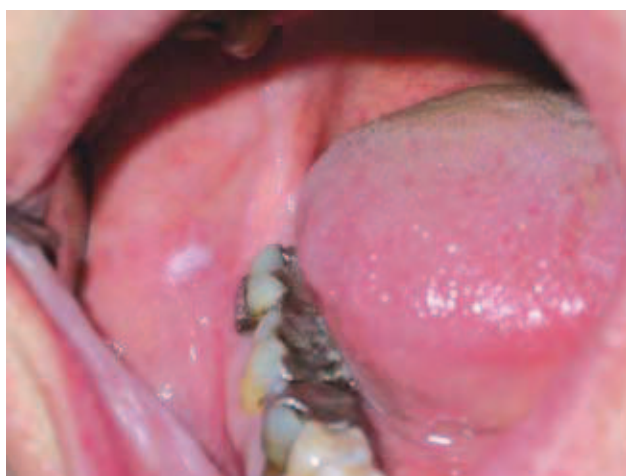

Figure 1

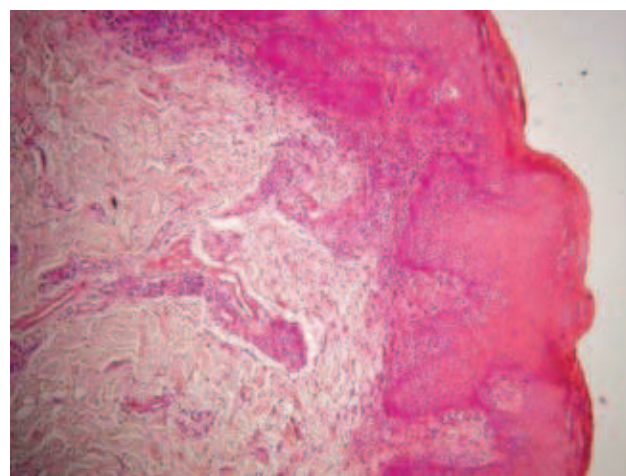


Figure 1

ARCHIVES OF HELLENIC MEDICINE 2011, 28(3):431–432
ΑΡΧΕΙΑ ΕΛΛΗΝΙΚΗΣ ΙΑΤΡΙΚΗΣ 2011, 28(3):431–432

N.G. Nikitakis,
G. Kamperos,
P. Argiris,
A. Sklavounou-Andrikopoulou

Department of Oral Medicine and
Pathology, School of Dentistry, National
and Kapodistrian University of Athens,
Greece

restorative material may be responsible for lichenoid reactions, but the vast majority of cases involve dental metals, especially amalgam. In order for a metal to become allergenic, it must first undergo corrosion and release metallic ions. Lichenoid reactions to precious metals are uncommon, most likely because these metals show low levels of intraoral corrosion. On the contrary, long lasting amalgam fillings show considerable corrosion. A positive patch test to the offending metal is frequently noticed in affected individuals, although a positive test alone does not necessarily indicate a true allergy. Dental and laboratory resins have also been implicated; nevertheless, it has been suggested that some of these cases can be attributed to excess monomer or poor polymerisation.

On clinical examination, the affected mucosa may be white or erythematous, with or without peripheral striae. These lesions are usually asymptomatic and may extend up to 1 cm beyond the mucosal association to the offending material. However these lesions do not migrate. This point along with the topographic correlation to an offending dental restoration and the usual lack of symmetric distribution is crucial for the diagnosis. A biopsy is advised to confirm the diagnosis and rule out epithelial dysplasia. The epithelium

may be hyperkeratotic, atrophic or ulcerated. Degeneration of the basal epithelial cell layer is observed as well as intense band-like lymphocytic infiltrate of the underlying connective tissue. As a result, the histopathologic features may be indistinguishable from oral lichen planus, although the frequent presence of perivascular infiltrates may point to an allergic reaction. Patch tests are not routinely prescribed nor considered necessary for the diagnosis.

Treatment usually involves replacing amalgam fillings with nonmetallic restorations or porcelain-fused-to-metal crowns. Polishing and smoothing of the old amalgam fillings may be attempted in case the patient does not concur to the replacement of the restorations. The lesions are expected to disappear in a period of several months. The malignant potential of lichenoid reactions is controversial and generally assumed to be quite rare. Nonetheless, patients should be monitored on a regular basis until complete resolution of the lesions.

References

1. AGGARWAL V, JAIN A, KABI D. Oral lichenoid reaction associated with tin component of amalgam restorations: a case report. *Am J Dermatopathol* 2010, 32:46–48
2. ISSAY, DUXBURY AJ, MACFARLANE TV, BRUNTON PA. Oral lichenoid lesions related to dental restorative materials. *Br Dent J* 2005, 198:361–366
3. ROBINSON NA. Lichenoid tissue reactions of the oral mucosa. *Singapore Dent J* 2000, 23(Suppl 1):56–63

Corresponding author:

N.G. Nikitakis, Department of Oral Pathology and Medicine, School of Dentistry, National and Kapodistrian University of Athens, 2 Thivon street, GR-11527 Goudi, Athens, Greece, Tel.: +30 2107461003, Fax: +30 2107461220
e-mail: nnikitakis1@yahoo.com