

CONTINUING MEDICAL EDUCATION ΣΥΝΕΧΙΖΟΜΕΝΗ ΙΑΤΡΙΚΗ ΕΚΠΑΙΔΕΥΣΗ

Oral Medicine and Pathology Quiz – Case 15

A 46-year-old male was referred to our clinic complaining of numerous ulcers in his oral cavity for the past 7 months. The patient had seen a number of clinicians and had received an original clinical diagnosis of oral squamous cell carcinoma located in the retromolar pad area. However, a biopsy of the retromolar ulcerative lesion had excluded malignancy but had failed to establish a specific final diagnosis. Various antiseptic mouthrinses and gels had been used on a daily basis without improvement. The patient used to be a heavy smoker (2 packs per day), but he had quit smoking two months ago. He did not receive any systemic medication and his medical history was otherwise unremarkable.

On clinical examination, the patient had several bilateral ulcerative lesions in buccal, vestibular and retromolar mucosa (figures 1a and b). In addition, redness of both eyes and genital ulcerations were noted in the absence of skin lesions (fig. 2). An incisional biopsy of the buccal mucosa lesion was performed and submitted for histopathologic and direct immunofluorescence (DIF) analysis. Microscopic examination showed acantholysis with intraepithelial cleft formation, as well as lymphocytic infiltration of the subepithelial connective tissue; DIF examination revealed IgG deposition among the epithelial cells. Based on the final diagnosis, the patient initially received a combined treatment of prednisolone (50 mg daily) and mycophenolate mofetil [MMF] (500 mg daily), along with gastroprotection. Systemic antifungal treatment was also added due to subsequent development of candidiasis. Full blood counts and hepatic enzymes were regularly monitored. Because of the duplication of the hepatic enzymes 8 weeks after treatment initiation, MMF was initially reduced to 250 mg daily for two weeks and subsequently replaced with azathioprine (100 mg daily). There was a gradual clinical improvement and, following 12 weeks of treatment, no residual lesions were present. Subsequent tapering of the medications maintained the therapeutic result and the patient remained under close observation, without recurrences or significant side effects.

Comment

Pemphigus vulgaris (PV) is a relatively uncommon autoimmune mucocutaneous blistering disease. It affects both sexes equally and the mean age of appearance is in the 5th to 6th decades. Oral

ARCHIVES OF HELLENIC MEDICINE 2011, 28(1):128–129
ΑΡΧΕΙΑ ΕΛΛΗΝΙΚΗΣ ΙΑΤΡΙΚΗΣ 2011, 28(1):128–129

**N.G. Nikitakis,
A. Sfakianou,
K. Delli,
A. Sklavounou-Andrikopoulou**

*Department of Oral Medicine and
Pathology, School of Dentistry, National
and Kapodistrian University of Athens,
Athens, Greece*

involvement appears in almost all patients during the course of the disease and in 50–60% of cases may precede skin lesions for several months. Oral lesions include blisters, which easily rupture forming chronic ulcers in various locations of the mouth. Another characteristic oral clinical manifestation is desquamative gingivitis. Nikolsky sign is positive.

Larynx, esophagus, conjunctiva, genital, nasal and anal mucosa may also be affected. Cutaneous lesions include the formation of blisters filled with clear fluid especially in areas of trauma, which rupture and coalesce to form rather extensive ulcers.

Systemic corticosteroids are the most commonly used therapeutic option for PV. Its use has significantly reduced mortality rate from 60–90% to below 10%, but multiple side effects associated with chronic use of steroids like diabetes, hypertension and osteoporosis point out the necessity of keeping patients under close monitoring. In addition, steroid-sparing agents including various immunosuppressive and immunomodulatory drugs are frequently used, although their side effects are also significant.

Mycophenolate mofetil has been successfully used in PV as monotherapy or in combination with steroids. Adverse effects of MMF include gastrointestinal disorders, genitourinary complaints, increased incidence of viral or bacterial infection and neurological symptoms. Absolute contraindications of MMF concern pregnancy and drug hypersensitivity.

Azathioprine is also one of the most commonly used adjuvant treatments in PV. Its administration increases the percentage of disease remission up to 45%. The drug can be even administered as sole therapy or as initial treatment. Its principal side effect is potentially severe myelosuppression.

Opportunistic infections are common side effects of all immunosuppressive medicinal products, including steroids. In the oral cavity, development of candidiasis is common, necessitating the administration of antifungal medications.

Pemphigus vulgaris treatment, especially management of the frequently persistent oral lesions, demands experience and flexibility for adjustments according to the clinical response and the potential side effects. Close follow-up, including blood tests, measurement of hepatic enzyme levels and alert for early detection and management of other potential side effects, is required.

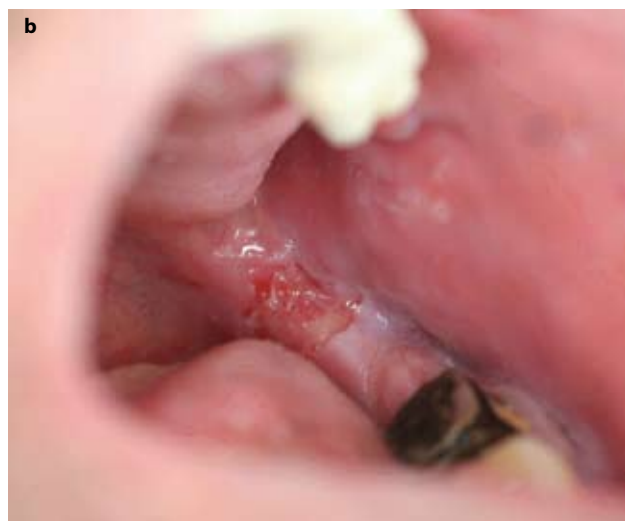
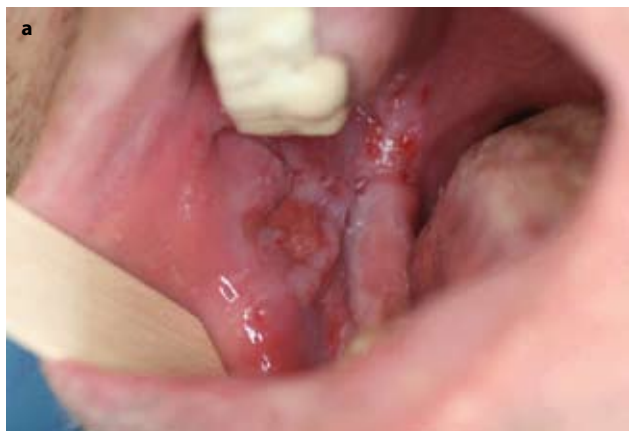
Figure 1. Ulcerative lesion in the right (a) and left (b) retromolar area during first clinical examination.

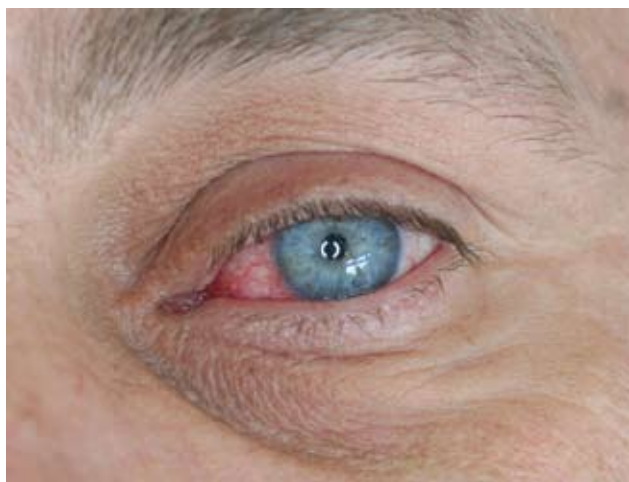


Figure 2. Redness of the conjunctival mucosa.

References

1. MIMOUNI D, ANHALT GJ, CUMMINS DL, KOUBA DJ, THORNE JE, NOUSARI HC. Treatment of pemphigus vulgaris and pemphigus foliaceus with mycophenolate mofetil. *Arch Dermatol* 2003, 139:739–742
2. SCULLY C, MIGNOGNA M. Oral mucosal disease: Pemphigus. *Br J Oral Maxillofac Surg* 2008, 46:272–277
3. PRAJAPATI V, MYDLARSKI PR. Advances in pemphigus therapy. *Skin Therapy Lett* 2008, 13:4–7

Corresponding author:

N.G. Nikitakis, Department of Oral Pathology and Medicine, School of Dentistry, National and Kapodistrian University of Athens, 2 Thivon street, GR-115 27 Athens, Greece, tel.: +30 210 74 61 003, fax: +30 210 7461220, e-mail: nnikitakis@yahoo.com

Diagnosis: Pemphigus vulgaris with mucosal involvement

