

CONTINUING MEDICAL EDUCATION ΣΥΝΕΧΙΖΟΜΕΝΗ ΙΑΤΡΙΚΗ ΕΚΠΑΙΔΕΥΣΗ

Vascular Diseases Quiz – Case 14

A 78-year-old male patient was referred to our department due to two large bilateral common iliac aneurysms, discovered during regular follow-up pelvic ultrasound study three years after prostatectomy for prostate cancer. At presentation, he was asymptomatic and clinical examination was unremarkable. His past medical history included ex-smoking, arterial hypertension, coronary artery disease, hyperlipidemia and prostate cancer. A spiral CTA scan was performed that revealed a 4.5 cm dilatation of the abdominal aorta, a 6.2 cm aneurysm of the right common and external iliac artery and a 6 cm aneurysm of the left common iliac artery up to the level of the common iliac bifurcation (fig. 1). A diagnostic angiogram was performed, which showed the detailed anatomy of the abdominal aorta and the internal iliac artery origin on both sides (fig. 2).

Quiz #1: Which is the optimum treatment strategy for this patient's condition?

Quiz #2: Is endovascular treatment feasible and safe?

Comment

A significant proportion of patients presenting for endovascular abdominal aortic aneurysm repair (EVAR) are found to have ectatic or aneurysmal common iliac arteries. In a number of these patients,

one or both distal common iliac arteries are unsuitable for use as a distal landing zone for the endograft. In such patients, EVAR usually necessitates the occlusion of one or both internal iliac arteries and extension of the stent graft into the external iliac artery. Various series have estimated that this is necessary in 15% to 30% of cases. Occlusion of one internal iliac artery (IIA) is usually achieved by coil embolization or the use of an occluding device. Such procedures are usually well tolerated, but not rarely may result in buttock claudication, post-procedure sexual dysfunction, and colonic ischemia. Complications are more likely and more serious after bilateral internal iliac artery occlusion. Sloughing of the scrotal skin, nonhealing decubitus ulcers, and ischemia to the lumbosacral plexus resulting in weakness and numbness to both lower limbs with bowel and bladder incontinence, have all been reported following bilateral internal iliac occlusion as part of EVAR. Although buttock claudication following unilateral internal iliac

ARCHIVES OF HELLENIC MEDICINE 2010, 27(2):277–278
ΑΡΧΕΙΑ ΕΛΛΗΝΙΚΗΣ ΙΑΤΡΙΚΗΣ 2010, 27(2):277–278

E. Psathas,
A. Katsargyris,
P. Roukanas,
S. Lioudaki,
C. Verikokos,
C. Klonaris

First Department of Surgery, Vascular
Division, Medical School, University of
Athens, "Laiko" General Hospital, Athens,
Greece

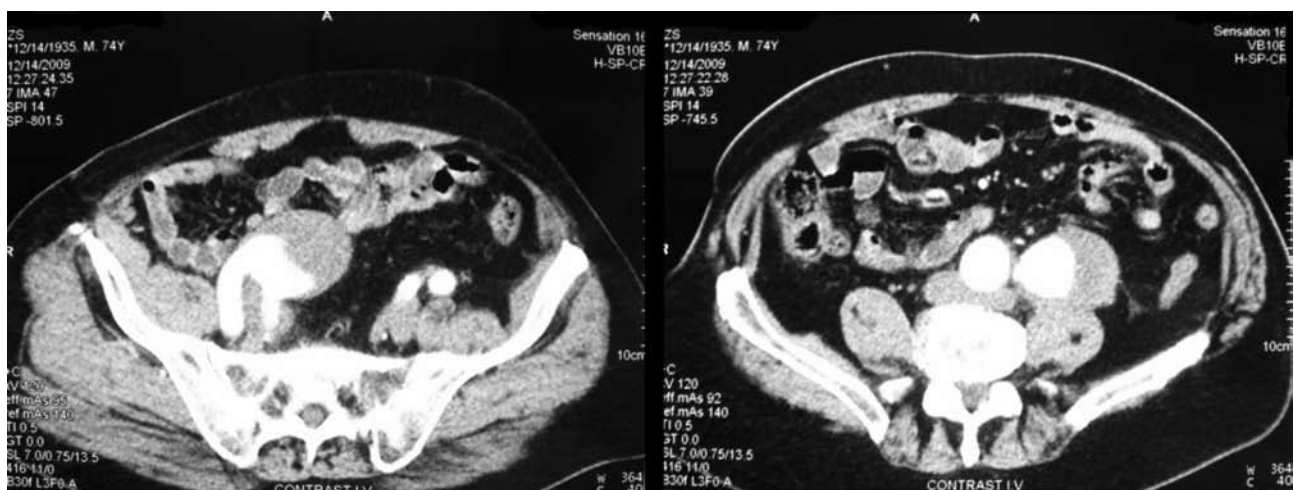

Figure 1. CTA scan of lower abdomen showed bilateral iliac artery aneurysms originating from the aortic bifurcation (right). The right common iliac aneurysm extends beyond the origin of the right internal iliac artery (left).

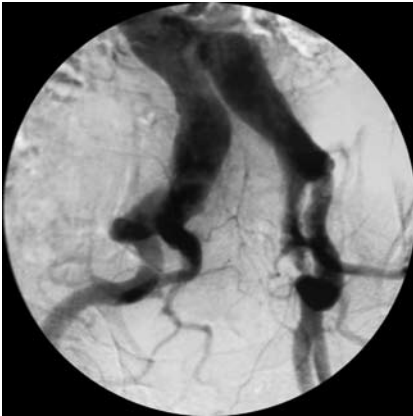


Figure 2. DSA of abdominal aorta and iliac arteries, identifying the exact origin of the IIA on both sides.

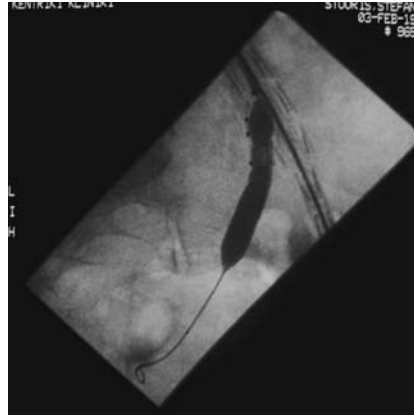


Figure 3. Deployment of the bifurcated iliac branch device and catheterization of the left IIA.

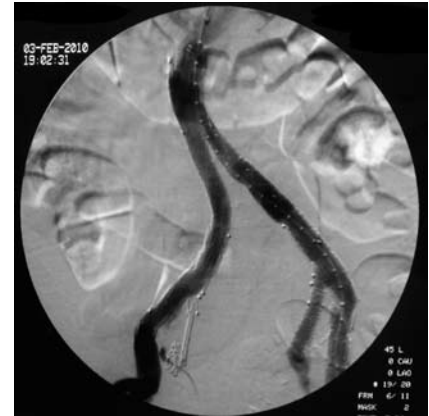

Figure 4. Completion angiogram demonstrating complete exclusion of the bilateral iliac aneurysms, with maintenance of blood flow to the left IIA via the IBD device, coil embolization of the right IIA and extension of both limbs to the external iliac artery, with no endoleak.

occlusion is usually considered as mild and transient, half of the patients remain symptomatic and are sufficiently debilitated.

Until recently, patients with abdominal aortic aneurysms (AAA) combined with bilateral iliac artery aneurysms involving both the internal iliac arteries were excluded from endovascular approach due to technical inability to maintain blood flow to at least one IIA. Hybrid techniques, combining endovascular exclusion of the IIA and open revascularization by means of external to internal iliac bypass grafting, reallocation of the origin of the internal iliac artery or aortouniliac grafting combined with femoro-femoral crossover grafting and retrograde grafting of the contralateral IIA, have been previously reported to be effective but they still remain invasive procedures, requiring laparotomy and significant retroperitoneal exposure. They therefore defeat the whole purpose of the minimally invasive nature of EVAR.

A bifurcated iliac side branch device (IBD) has been recently invented in order to preserve internal iliac artery flow following EVAR in such patients. This device resembles a standard limb extension, but has a side branch attached to its body approximately half way down its length as shown in figure 3. The device is tailored to the patient's anatomy based on the length of the common iliac artery

aneurysm and the length and diameter of the external iliac artery, measured during preoperative imaging.

The patient discussed herein was successfully treated with placement of such an IBD to maintain blood flow to the left IIA, coil embolization of the right IIA, and deployment of a bifurcated stent-graft to totally exclude the iliac aneurysms (fig. 4). The whole intervention was performed under local anesthesia and mild sedation with a mean operative time of 76 min. The patient's postoperative course was uncomplicated and hospitalization was 3 days.

Patients with aortoiliac aneurysms involving the internal iliac arteries can now be offered a new alternative less complex and less invasive endovascular therapy with the use of side-branch devices. Such a treatment provides safe and effective exclusion of the aneurysm while maintaining also pelvic blood flow.

Corresponding author:

C. Klonaris, First Department of Surgery, Vascular Division, Medical School, University of Athens, "Laiko" General Hospital, Athens, Greece
e-mail: chris_klonaris@yahoo.com