

CONTINUING MEDICAL EDUCATION ΣΥΝΕΧΙΖΟΜΕΝΗ ΙΑΤΡΙΚΗ ΕΚΠΑΙΔΕΥΣΗ

Hematology Quiz – Case 17

The physical examination revealed pallor, purpura in the lower extremities and signs of bleeding in his gums. The full blood count revealed hemoglobin of 9.1 g/dL, a white cell count of $34 \times 10^9/L$, neutrophil count of $0.7 \times 10^9/L$ and a platelet count of $7 \times 10^{12}/L$. Peripheral blood smears revealed the presence of abnormal cells with basophilic granules (fig. 1). Other laboratory testing was remarkable for a serum urea of 55 mg/dL, creatinine 2.1 mg/dL and LDH 2,160 U/dL. Chest X-rays revealed no abnormalities. The bone marrow aspirate was grossly hypercellular with normal hematopoiesis replaced by a population of abnormal cells, accounting for 65% of nucleated cells and eosinophils, and their precursors, accounting for 22% of nucleated cells (fig. 2). No Auer rods were seen although some abnormal cells contained fine granules. Cytochemically, these cells were positive for Sudan black and chloracetate esterase and 27% of nucleated marrow cells showed weak staining with non-specific esterase. Immunophenotyping showed positivity for myeloperoxidase, CD33, CD34, HLA-DR, CD117, CD13, CD64 and CD15, and B- and T-cell markers were negative. Cytogenetic analysis of bone marrow revealed 46,XY,t(16;16)(p13;q22) in all 20 metaphase cells. The diagnosis was made and the patient received appropriate induction chemotherapy with posaconazole prophylaxis.

On day 16 of induction therapy, he became febrile and was started on empirical ceftazidime and amikacin according to creatinine clearance, as he was neutropenic (neutrophils $0.1 \times 10^9/L$). The chest X-ray showed a dense infiltrate in the right lower lobe (fig. 3). Vancomycin and voriconazole were added two days later as the fever had not been resolved and the patient remained in severe neutropenia. The thoracic high resolution computed tomography (HRCT) performed on d 5 of the fever and showed

also a cavitating infiltrate with halo sign in the left lower lobe. The CT was highly suspicious of invasive aspergillosis and the patient was started on a combination therapy consisting of amphotericin B 1.5 mg/kg iv q.d. and voriconazole 4 mg/kg iv q12 h. Ceftazidime was replaced by imipenem and vancomycin continued. A bronchoalveolar lavage failed to document an active infection with negative Gram, Grocott and acid-fast stains as well as negative cultures, but there was a positive polymerase chain reaction for *Aspergillus*. Follow-up CT scans (on d 15 and d 40) showed a reduction of the cavitary infiltrate. The patient

ARCHIVES OF HELLENIC MEDICINE 2010, 27(1):134–135
ΑΡΧΕΙΑ ΕΛΛΗΝΙΚΗΣ ΙΑΤΡΙΚΗΣ 2010, 27(1):134–135

J. Meletis,¹
A. Sarantopoulos,¹
J.V. Asimakopoulos,¹
T. Chatzileonida,¹
E. Papakostas,¹
E. Bazani,¹
M. Michael,¹
A. Anastasopoulou,¹
E. Chouliara,¹
O. Kampouroupolou,¹
E. Variami,¹
N. Viniou,¹
K. Konstantopoulos,¹
E. Terpos²

¹First Department of Internal Medicine, National and Kapodistrian University of Athens, School of Medicine, "Laiko" General Hospital, Athens

²Department of Clinical Therapeutics, National and Kapodistrian University of Athens, School of Medicine, "Alexandra" General Hospital, Athens, Greece

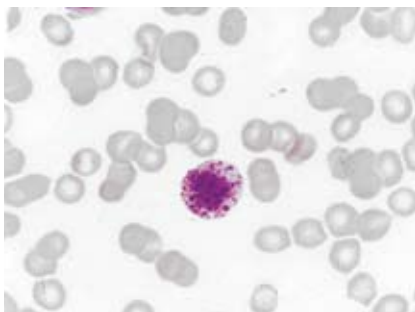


Figure 1

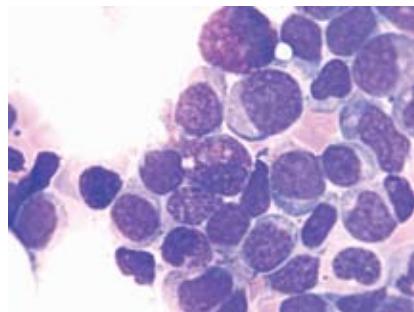


Figure 2

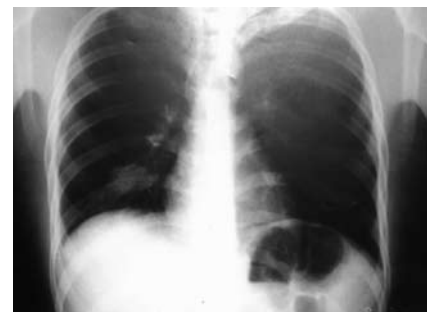

Figure 3

was without fever from the 5th day of the antifungal combination therapy.

Comment

The presence of the *inv(16)(p13.1q22)* or *t(16;16)(p13.1;q22)* in patients with acute myeloid leukemia (AML) describes a new category of AML in the WHO 2008 classification for acute myeloid leukemia (tab. 1) in an attempt to better define prognosis in some AML subtypes and to propose specific treatment mainly when targeted therapies become available. This type of AML is accompanied by an increase in eosinophil lineage and eosinophils are part of the clone. Induction chemotherapy with daunorubicin or idarubicin in combination with cytosine arabinoside remains the cornerstone for induction therapy in AML patients. Neutropenic fever is very common during such therapies. Breakthrough fungal infections during empirical antifungal prophylaxis in febrile neutropenia are a well-known problem. Posaconazole has

been licensed for use as a prophylactic antifungal agent in patients with AML who receive cytotoxic therapy. In our case, the patient developed a pulmonary Aspergillosis, which was successfully treated with the combination of voriconazole and amphotericin B. There is only a large multicentre trial, which compared voriconazole against amphotericin B in febrile neutropenia, and revealed four breakthrough invasive fungal infections due to susceptible *Aspergillus* species out of a total of 415 (1%) patients treated with voriconazole, compared to 13 out of 422 patients (3.1%) in the group treated with liposomal amphotericin B. This suggests a high efficacy of voriconazole in preventing the development of invasive *Aspergillus* infections in febrile neutropenia. That is why we had added voriconazole in the regimen of the patients after two days of fever. In addition, within a series of 139 stem-cell transplant recipients receiving voriconazole as antifungal prophylaxis, there were 2 more cases mentioned of breakthrough infections due to *Aspergillus* species. One of the cases developed invasive pulmonary aspergillosis due to *Aspergillus terreus* and 1 a disseminated disease due to *Aspergillus ustus*. Both patients died of these infections.

In conclusion, we have to keep in mind that breakthrough fungal infections can be easily happened in patients with AML during cytotoxic therapies despite theoretically appropriate antifungal therapy. Only larger, multicentre trials will inform us about the frequency of breakthrough fungal infections despite posaconazole or voriconazole prophylaxis in immunocompromised hosts.

Table 1. Acute myeloid leukemia (AML) and related neoplasms.

Acute myeloid leukemia with recurrent genetic abnormalities
AML with <i>t(8;21)(q22;q22)</i> ; <i>RUNX1-RUNX1T1</i>
AML with <i>inv(16)(p13.1q22)</i> or <i>t(16;16)(p13.1;q22)</i> ; <i>CBFB-MYH11</i>
APL with <i>t(15;17)(q22;q12)</i> ; <i>PML-RARA</i>
AML with <i>t(9;11)(p22;q23)</i> ; <i>MLL3-MLL</i>
AML with <i>t(6;9)(p23;q34)</i> ; <i>DEK-NUP214</i>
AML with <i>inv(3)(q21q26.2)</i> or <i>t(3;3)(q21;q26.2)</i> ; <i>RPN1-EVI1</i>
AML (megakaryoblastic) with <i>t(1;22)(p13;q13)</i> ; <i>RBM15-MKL1</i>
AML with mutated NPM1
AML with mutated CEBPA
Acute myeloid leukemia with myelodysplasia-related changes
Therapy-related myeloid neoplasms
Acute myeloid leukemia, not otherwise specified
AML with minimal differentiation
AML without maturation
AML with maturation
Acute myelomonocytic leukemia
Acute monoblastic/monocytic leukemia
Acute erythroid leukemia
Pure erythroid leukemia
Erythroleukemia, erythroid/myeloid
Acute megakaryoblastic leukemia
Acute basophilic leukemia
Acute panmyelosis with myelofibrosis
Myeloid sarcoma
Myeloid proliferations related to Down syndrome
Transient abnormal myelopoiesis
Myeloid leukemia associated with Down syndrome
Blastic plasmacytoid dendritic cell neoplasm

References

- BAIN BJ. *Leukemia diagnosis*. 3rd ed. Blackwell Publ, Oxford, 2003:90–97
- SVERDLOW SH, CAMPO E, HARRIS NL, JAFFE ES, PILERI SA, STEIN H ET AL (eds). *WHO classification of tumours of hematopoietic and lymphoid tissues*. 4th ed. WHO Press, Geneva, 2008:111–112
- MELETIS J. *Atlas of hematology*. 3rd ed. Nireas Publ. Inc, Athens, 2009:368–374
- VARDIMAN JW, THIELE J, ARBER DA, BRUNNING RD, BOROWITZ MJ, PORWIT A ET AL. The 2008 revision of the World Health Organization (WHO) classification of myeloid neoplasms and acute leukemia: Rationale and important changes. *Blood* 2009, 114:937–951
- IMHOF A, BALAJEE SA, FREDRICKS DN, ENGLUND JA, MARR KA. Breakthrough fungal infections in stem-cell transplant recipients receiving voriconazole. *Clin Infect Dis* 2004, 39:743–746
- MARTY FM, COSIMI LA, BADEN LR. Breakthrough zygomycosis after voriconazole treatment in recipients of hematopoietic stem-cell transplants. *N Engl J Med* 2004, 350:950–952

Corresponding author:

J. Meletis, First Department of Internal Medicine, National and Kapodistrian University of Athens, School of Medicine, "Laiko" General Hospital, Athens, Greece, tel.: +30 210 74 66 206, fax: +30 210 7788830
e-mail: imeletis@cc.uoa.gr

.....
Diagnosis: AML with *t(16;16)(p13.1;q22)* (previous *M4e0s*) and pulmonary aspergillosis