

## CONTINUING MEDICAL EDUCATION ΣΥΝΕΧΙΖΟΜΕΝΗ ΙΑΤΡΙΚΗ ΕΚΠΑΙΔΕΥΣΗ

### Thoracic Surgery Quiz – Case 8

A 39-year-old man was admitted to the emergency department due to permanent frontal headaches, unable to confront with usual analgesics (paracetamol, NSAIDs). He noted on his past medical history that he had been suffering from frequent episodes of pulse sensation, high blood pressure and sweating.

On physical examination he had high blood pressure and tachycardia. The rest of the examination was normal. The patient was admitted for further examinations.

The routine laboratory tests were within normal limits. Liver and kidney function was very good. He underwent a heart ultrasound, which only revealed hypertrophy of interventricle septum. As the patient's symptoms could not be explained by this, he undertook an ultrasound scan of kidneys and a triplex sonography of kidney vessels, where an enlargement of the right adrenal gland was revealed. Further investigations included CT scan and MRI scan (figures 1, 2, 3); a tumour of the right adrenal gland was found, about 7 cm in diameter, with necrotizing, but not hemorrhagic features, of high uptake of contrast media.

Additional laboratory test were sent to identify the origin and the potential malignancy of the tumour; CgA level: 494 (normal 19.4–98.1 ng/mL); 24h urine metanephrines, catecholamine and vanillymandelic acid: adrenaline: 59 (normal 1.7–22.4 µg/24h); noradrenaline: 612 (12.1–85.5 µg/24h); dopamine: 450 (normal 65–400 µg/24h); VMA: 32.7 (normal 1.7–22.4 µg/24h); metanephrine:

1,517 (normal 52–341 µg/24h); normetanephrine: 9,868 (normal 88–444 µg/24h). The scanning test with radionuclide  $^{131}\text{I}$  showed an increased uptake at the place of the right adrenal gland.

He was further treated with phenoxybenzamine (Dibenzyline) and was referred to our Department for surgical excision of the lesion, with the diagnosis of pheochromocytoma (fig. 4). Treatment consisted of right adrenalectomy with the flank approach under general anesthesia.

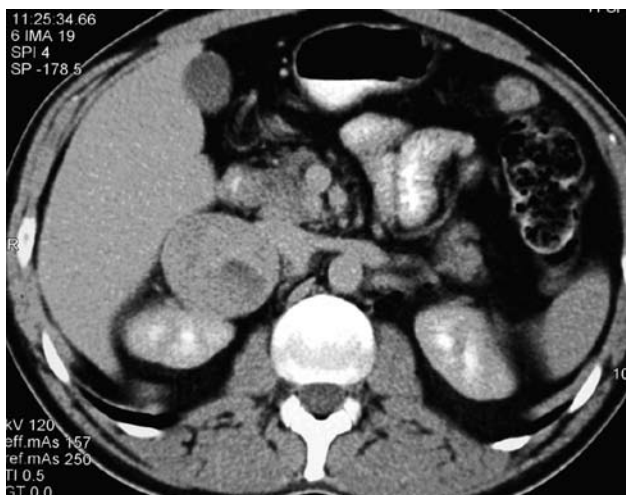

Figure 1

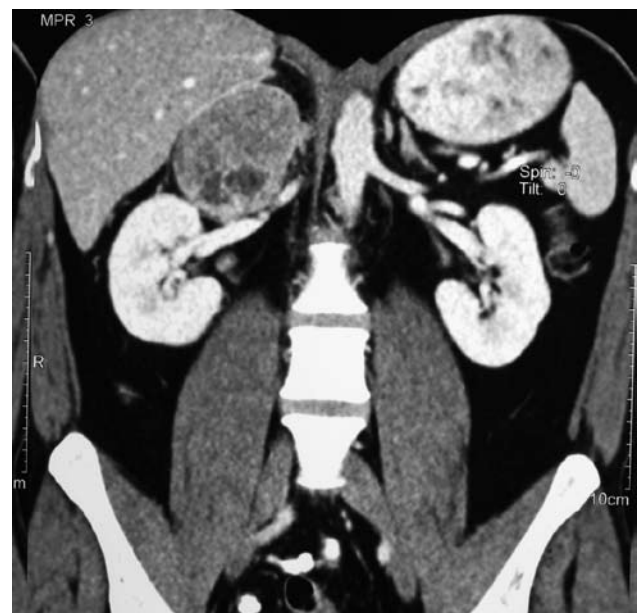


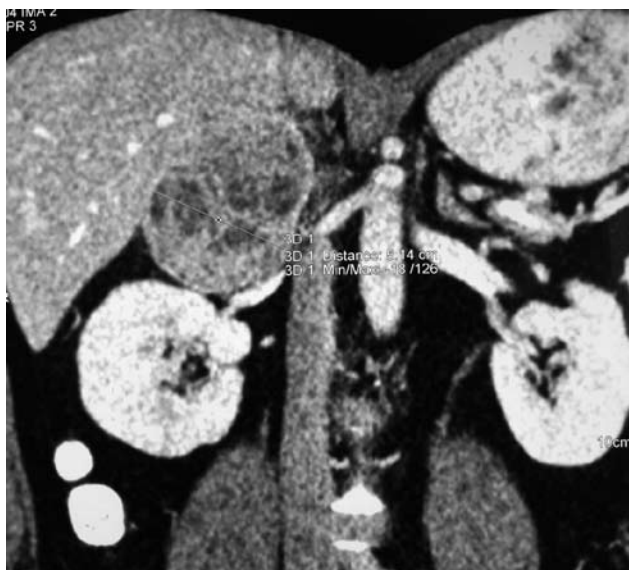Figure 2

ARCHIVES OF HELLENIC MEDICINE 2009, 26(5):716–717  
ΑΡΧΕΙΑ ΕΛΛΗΝΙΚΗΣ ΙΑΤΡΙΚΗΣ 2009, 26(5):716–717

D. Patsouras,<sup>1</sup>  
P. Paraskeva,<sup>1</sup>  
E. Spartalis,<sup>1</sup>  
S. Kykalos,<sup>1</sup>  
P. Katsaronis,<sup>1</sup>  
P. Roussaki,<sup>2</sup>  
A. Boutsarakis,<sup>1</sup>  
N. Nikiteas,<sup>1</sup>  
P. Tomos<sup>1</sup>

<sup>1</sup>Second Department of Propedeutic Surgery

<sup>2</sup>Department of Pathologic Physiology, National and Kapodistrian University of Athens, Medical School, "Laiko" General Hospital of Athens, Athens, Greece



**Figure 3**

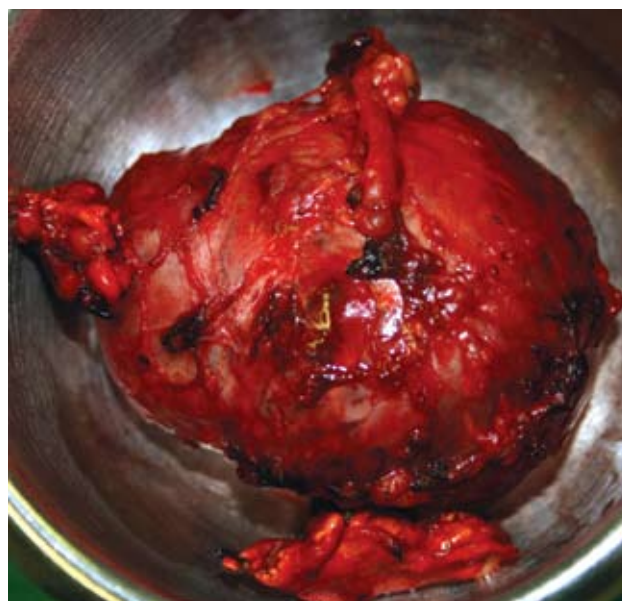
His clinical symptoms improved within the next days. The 24h urine metanephrines, catecholamine and vanillylmandelic acid measurements postoperatively were within normal limits: adrenaline: 3; noradrenaline: 23; dopamine: 236; VMA: 4.1; metanephrine: 75; normetanephrine: 170. Pathologic examination of the specimen revealed pheochromocytoma.

The patient recovered and was discharged home 5 days after the operation under the medical directions of the endocrinologist.

### Comment

*Adrenal gland tumours arise from either the adrenal medulla or the adrenal cortex and can be benign or malignant. The adrenal cortex is composed of three distinct layers of endocrine cells, which produces critical steroid hormones. Tumours of the adrenal cortex are adrenocortical adenoma and adrenocortical carcinoma. The adrenal medulla is located anatomically at the centre of each adrenal gland and is composed of neuroendocrine cells, which produce and release epinephrine into the bloodstream in response to activation of the sympathetic nervous system. Neuroblastoma and pheochromocytoma are the two most important tumours, arising from the adrenal medulla.*

*Surgical treatment of the adrenal tumours is usually performed with the flank approach; the incision is made over or along the chosen rib (11th or 12th) towards the umbilicus. It is particularly useful in massively obese patients. If both glands need to be removed, the surgeon has to perform two incisions at both sides. The extraperitoneal, extrapleural 11th or 12th rib flank approach, as used for a radical nephrectomy, provides excellent exposure for*



**Figure 4**

*right or left adrenalectomy.*

### References

1. TOWNSEND CM, BEAUCHAMP RD, EVERS BM, MATTOX KL. *Sabiston textbook of surgery*. 18th ed. Saunders, Elsevier, Philadelphia, 2007
2. ZHOU GW, WEI Y, CHEN X, JIANG XH, LI XY, NING G ET AL. Diagnosis and surgical treatment of multiple endocrine neoplasia. *Chin Med J (Engl)* 2009, 122:1495–1500
3. PORTELA-GOMES GM, STRIDSBERG M, GRIMELIUS L, FALKMER UG, FALKMER S. Expression of chromogranins A, B, and C (secretogranin II) in human adrenal medulla and in benign and malignant pheochromocytomas. An immunohistochemical study with region-specific antibodies. *APMIS* 2004, 112:663–673
4. THOMPSON LD. Pheochromocytoma of the Adrenal gland Scaled Score (PASS) to separate benign from malignant neoplasms: A clinicopathologic and immunophenotypic study of 100 cases. *Am J Surg Pathol* 2002, 26:551–566
5. GULLÀ N, PATRITI A, FABBRI B, LAZZARINI F, FABBRI C, TRISTAINO B. Surgical technique and haemodynamic changes in adrenalectomy for secreting neoplasia. Personal experience and review of the literature. *Minerva Chir* 2003, 58:87–92

*Corresponding author:*

P.P. Paraskeva, "Laiko" Hospital, 17 Mikras Asias street, GR-115 27 Athens, Greece

e-mail: noraparaskeva@hotmail.com

*Diagnosis: Right adrenal pheochromocytoma*