

## CONTINUING MEDICAL EDUCATION ΣΥΝΕΧΙΖΟΜΕΝΗ ΙΑΤΡΙΚΗ ΕΚΠΑΙΔΕΥΣΗ

### Thoracic Surgery Quiz – Case 6

A 67-year-old man with a history of hypertension, hyperlipidemia, impaired glucose tolerance, coronary artery disease, peripheral vascular disease, chronic renal failure and aneurysm of abdominal aorta was admitted to this hospital with a three-month history of recurrent fevers and fatigue. These symptoms had begun soon after he had undergone coronary artery bypass grafting (CABG).

He had initially been treated by his physician with a 7-day course of cefuroxime. Due to persistence of the symptoms the patient was admitted to a local hospital. Blood cultures and culture from the post-sternotomy wound were obtained. The culture from the surgical wound was positive for *Staphylococcus epidermidis* (fig. 1). A transesophageal echocardiogram was normal. After initial antibiotic therapy with vancomycin, he was discharged with instructions to complete therapy with linezolid. The antibiotic therapy was discontinued three weeks later due to thrombocytopenia and anemia caused by linezolid.

However, one week after finishing the antibiotics he reported the recurrence of fever, fatigue-malaise and also symptoms of upper respiratory infection. He was admitted to this hospital. After hospital admission the patient remained asymptomatic. No antipyretics or antibiotics were given. He was rechecked for sternal wound infection even though no indications were present. An x-ray of the sternum, an ultrasound of the soft-

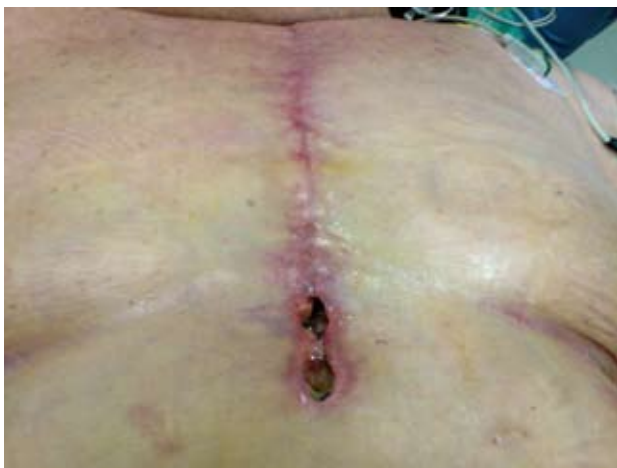


Figure 1

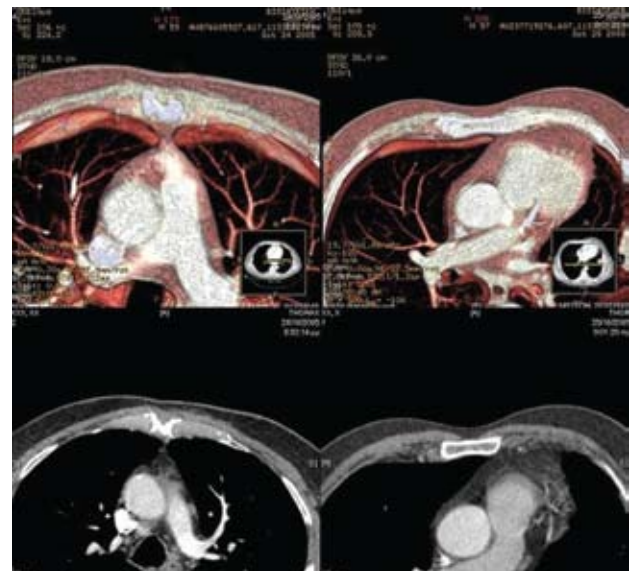


Figure 2

ARCHIVES OF HELLENIC MEDICINE 2009, 26(2):283-284  
ΑΡΧΕΙΑ ΕΛΛΗΝΙΚΗΣ ΙΑΤΡΙΚΗΣ 2009, 26(2):283-284

L. Hadjihannas,<sup>1</sup>  
P. Paraskeva,<sup>2</sup>  
P. Katsaronis,<sup>2</sup>  
M. Psychogiou,<sup>1</sup>  
P. Tofas,<sup>1</sup>  
L. Lekakos,<sup>2</sup>  
G. Daikos,<sup>1</sup>  
P. Tomos<sup>2</sup>

<sup>1</sup>First Department of Propedeutic  
Internal Medicine,

<sup>2</sup>Second Department of Propedeutic  
Surgery, National and Kapodistrian  
University of Athens, Medical School,  
"Laiko" General Hospital, Athens, Greece

tissues and sternum, a computer tomography of the chest and a transthoracic echocardiogram were performed (fig. 2). The results of these tests were unremarkable. He was discharged with instructions for close surveillance.

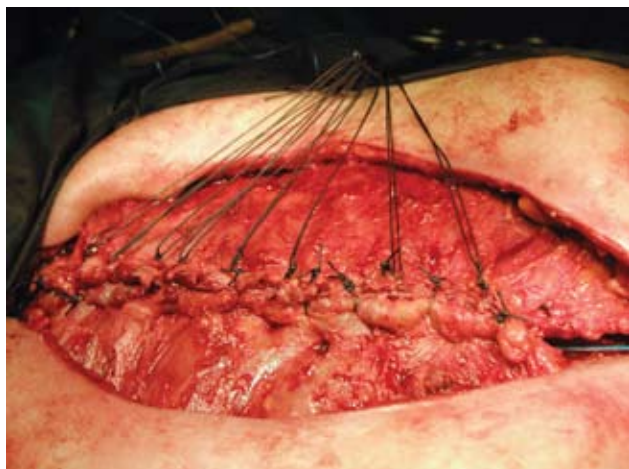His fever recurred five days later. He was readmitted to the hospital. On physical examination he appeared well. The temperature was 38.3 °C, blood pressure 135/85 mmHg, pulse 92 beats per minute. The cardiovascular examination showed a regular rhythm with no murmurs. His lungs were clear on auscultation. The sternal incision was healing. No tenderness

on palpation of the sternum was noticed. The remainder of the physical examination was normal.

Laboratory findings revealed an elevated erythrocyte sedimentation rate of 74 mm/h (0–20), elevated C-reactive protein of 143 mg/L (0–5), and elevated white blood cell count of 15.3 k/UL (4.0–10.0). The hemoglobin was 10.7 g/dL (14–18), the hematocrit was 32.7% (38.0–52.0) and the mean corpuscular volume was 88.3 fL (81.0–99.0). The platelet count was 715 k/ $\mu$ L (140–440). The creatinine level was 1.9 mg/dL (0.7–1.4) and the urea level was 79 mg/dL (17–50).

Serial blood cultures were obtained. Two cultures were positive for *Staphylococcus epidermidis*. A three-phase bone scan with Technetium 99m showed hyperemia and focally increased uptake of the radionuclide in the region of the sternal manubrium. A Gallium-67 whole-body scan showed no findings to suggest focal active infection. A three-dimensional computer tomography of the chest revealed heterogeneity in the region of the sternal manubrium and directly below the manubriosternal joint. Mild thickening of the soft tissue in the vicinity of the sternum and of the retrosternal space was noticed.

Ten days after his admission, the patient was taken to the operating room. A “V” shaped sternectomy was performed. During the surgical procedure all of the necrotic soft tissue, cartilage and wires were removed. The midline of the sternum was scraped to form a “V”. Bi-pectoral musculofascial flaps were created. The medial ends of the flaps were brought toward the midline and buried in the sternal defect (fig. 3). The humeral insertion



**Figure 3**

and thoracoacromial vessels were left intact. Ciprofloxacin and clindamycin were given to the patient as perioperative antibiotic prophylaxis. Cultures of the excised material were positive for *Staphylococcus epidermidis*. Treatment with teicoplanin and rifampicin was initiated.

The patient's postoperative course was complicated by the recurrence of fever. The workup for the source of his fever included transesophageal echocardiogram and computer tomography of the chest and abdomen. The transesophageal echocardiogram revealed an aortic valve vegetation. Serial blood cultures were negative. The patient completed 6-weeks course of vancomycin and rifampicin.

### Comment

*Deep sternal wound infection (DSWI) is associated with sternal osteomyelitis with or without infected retrosternal space (bone and mediastinitis). Deep sternal wound infection (DSWI) is an infrequent, yet potentially devastating complication following coronary artery bypass grafting (CABG). This complication is associated with increased cost of care, prolonged hospitalization, and increased morbidity and mortality. The reported incidence of DSWI ranges between 0.7% and 3.9%, and the reported in-hospital mortality can be as high as 14%. The exact mechanism by which DSWI develops is not fully understood and is thought to be multifactorial. However, many risk factors have been identified as independent predictors for DSWI following CABG, which include preoperative (e.g., sex, age, obesity, diabetes mellitus, grade III and IV NYHA score, COPD, reoperation, steroids use, smoking, peripheral vascular disease, renal insufficiency, Staphylococcus aureus nasal carriage), intraoperative (e.g., use of bilateral internal thoracic arteries, antibiotic prophylaxis, operation time), and postoperative variables (e.g., prolonged mechanical ventilation, reexploration for bleeding, postoperative transfusions, and nephrologic and pulmonary complications). Management of sternal osteomyelitis is still difficult and is a subject of controversy.*

*Deep sternal infection can be a potential septic focus for infective endocarditis.*

*“Alternative bi-pectoral muscle flaps” is a surgical procedure proposed by Tomos et al, for the treatment of postoperative deep sternal wound infection.*

Corresponding author:

P.P. Paraskeva, “Laiko” Hospital, 17 Mikras Asias street, GR-115 27 Athens, Greece  
e-mail: noraparaskeva@hotmail.com