

## CONTINUING MEDICAL EDUCATION ΣΥΝΕΧΙΖΟΜΕΝΗ ΙΑΤΡΙΚΗ ΕΚΠΑΙΔΕΥΣΗ

### Thoracic Surgery Quiz – Case 2

A 63-year-old woman was admitted due to worsening substernal chest pain and dry cough of 8 months duration. For the past 3 months she had also been suffering from dysphagia, which initially involved solid foods but over the past few days extended to liquids as well. Her surgical history included removal of a meningioma and a vertical banded gastroplasty for morbid obesity combined with a cholecystectomy, performed 12 and 10 years earlier respectively. She was on  $\beta$ -adrenergic blockers for hypertension for the last decade. 8 months before admittance to our clinic, she had visited another clinic due to substernal chest pain. At that time a heart condition was ruled out with an echocardiogram, stress testing and stress perfusion imaging. Barium esophagography revealed erosive esophagitis and a minor esophageal hiatus hernia. A diagnosis of GERD was established and a proton pump inhibitor was prescribed, that led to reduction but not elimination of the chest pain of the patient. While still on the proton pump inhibitor, her dysphagia was aggravated and started to extend to liquids in addition to solid foods. A reassessment of the patients' diagnosis was deemed necessary.

On examination her general condition was good, with a heart rate of 80 bpm and blood pressure of 130/70 mmHg. Physical examination of the heart and lungs as well as an ECG and a chest X-ray did not reveal any abnormal findings, thus excluding a cardiac or pulmonary etiology. The initial laboratory workup revealed only a mild anemia, with a hematocrit of 34%. The differential diagnosis included esophageal hiatus hernia, GERD with esophagitis and esophageal stricture, esophageal motility disorders such as achalasia, diffuse esophageal spasm, and esophageal malignancy. A chest CT did not show any mediastinal or esophageal mass lesions but revealed a fluid filled esophagus with an air-fluid level (fig. 1). On barium esophagography dilation of the esophagus, loss of primary peristalsis, and a smooth tapering of the distal esophagus (fig. 2) were evident and the esophageal manometry revealed esophageal body aperistalsis and incomplete LES relaxation. The above findings were compatible with a diagnosis of achalasia.

A decision to proceed with surgical treatment was made and a transthoracic Heller esophagocardiomyotomy with a partial Dor fundoplication were performed (fig. 3). A laparoscopic approach was not chosen because of the previous upper

abdominal surgery.

The patient was discharged on the 5th postoperative day, on a regular diet showing complete remission of her symptoms and a normal barium esophagography. Histologic examination of an esophageal tissue specimen revealed denervation of the myenteric plexus consistent with achalasia.

#### Comment

*Many patients with esophageal achalasia are initially misdiagnosed with GERD, since nearly 40% of them complain of some degree of heartburn due to poor clearance of refluxed*

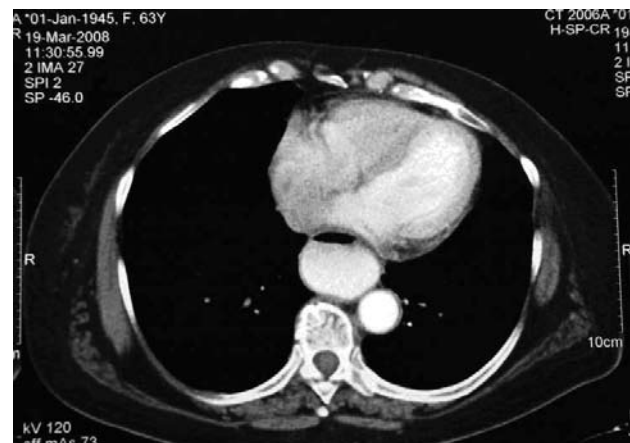


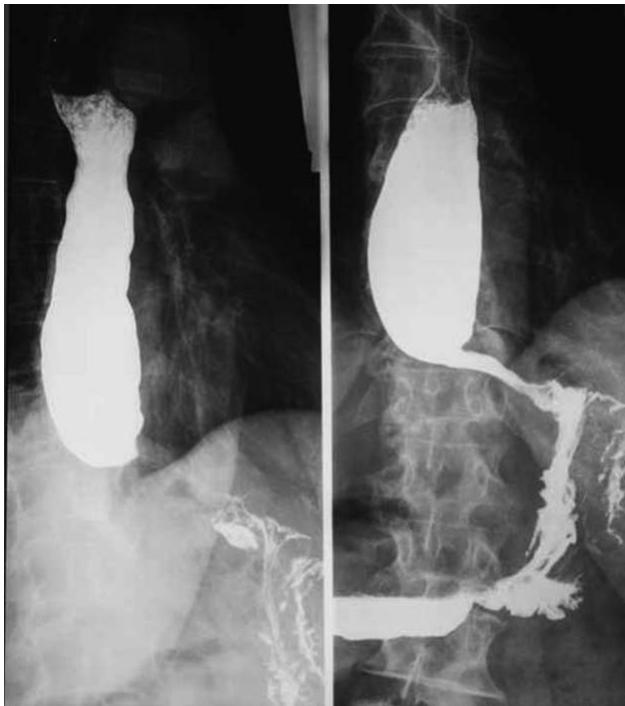Figure 1

ARCHIVES OF HELLENIC MEDICINE 2008, 25(4):544–545  
ΑΡΧΕΙΑ ΕΛΛΗΝΙΚΗΣ ΙΑΤΡΙΚΗΣ 2008, 25(4):544–545

C. Markakis,<sup>1</sup>  
C.S. Floudas,<sup>2</sup>  
K. Konstantoudakis,<sup>1</sup>  
P. Katsaronis,<sup>1</sup>  
A. Smirnis,<sup>1</sup>  
S. Kikalos,<sup>1</sup>  
P. Tomos<sup>1</sup>

<sup>1</sup>2nd Department of Propedeutic Surgery,

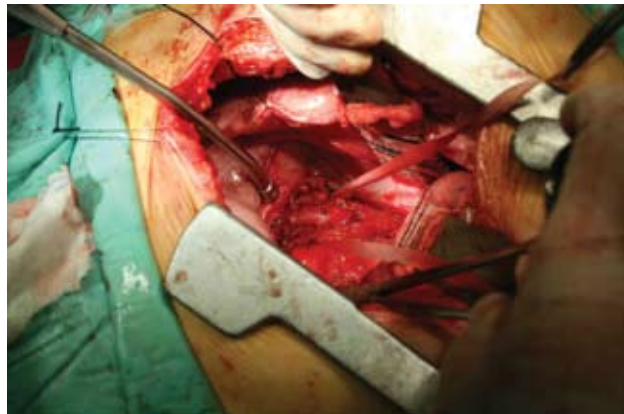<sup>2</sup>First Department of Internal Medicine, National and Kapodistrian University of Athens, Medical School, "Laiko" General Hospital of Athens, Athens, Greece



**Figure 2**

gastric acid. Upon further questioning, the most common complaint in achalasia is dysphagia for both solid food and liquids, with regurgitation of saliva and undigested food. Most patients will have some degree of weight loss, which is usually moderate. About 40% of patients will complain of substernal chest pain. Failure to recognize achalasia may result in ineffective medical therapy or Nissen fundoplication for GERD and worsening symptoms of reflux. It is important to thoroughly evaluate dysphagia in patients with heartburn and regurgitation, since the correct surgical intervention will either provide a definite cure or a significant improvement in the symptoms and quality of life of the patient.

Esophagocardiomyotomy was introduced by Ernest Heller in 1914 and remains the most effective long-term treatment for



**Figure 2**

achalasia. It is combined with a partial (Dor or Toupet) fundoplication with excellent results. A 360-degree fundoplication should not be used in this setting as it can lead to obstructive symptoms. With advances in videoscopic technology in the early 1990s, the open operation was readily replaced by a minimally invasive laparoscopic approach. The thoracic approach is thus best reserved for reoperative Heller myotomy, incomplete proximal myotomy, and hostile upper abdomen, as was the case with our patient. For patients who are poor candidates for surgery, forceful pneumatic dilatation has a success rate of up to 90%, but also entails a high risk of perforation (3–12%). Botulinum toxin injection is not as effective and complicates subsequent surgical operations with a high (30%) perforation rate, but can be used in patients who have a high operative risk and are unsuitable for balloon dilatation due to a dilated sigmoid esophagus. The efficacy of the surgical approach, combined with the reduced morbidity of the minimally invasive techniques, has established it as the treatment of choice for achalasia.

Corresponding author:

C.S. Floudas, 50 Alexandroupoleos street, GR 115-27 Athens, Greece  
 e-mail: chfloudas@gmail.com