

CONTINUING MEDICAL EDUCATION ΣΥΝΕΧΙΖΟΜΕΝΗ ΙΑΤΡΙΚΗ ΕΚΠΑΙΔΕΥΣΗ

Surgery Quiz – Case 3

A 21-year-old man from Syria presented at the emergency department complaining for epigastric pain with gradual onset since 6 days, accompanied by low-grade fever, nausea and fatigue. The patient reported reflection of the pain to the right upper quadrant (RUQ) over the last two days, associated with accentuation of the initial complaint and discoloration of the skin. No relation to food intake was noted. Past medical history included the presence of a liver hydatid cyst four years ago which was diagnosed following spontaneous rupture into the peritoneal cavity causing acute abdomen. The patient underwent emergency surgery which included open pericystectomy, partial right hepatectomy and cholecystectomy through a transverse and a midline incision. The duration of postoperative antihelminthic therapy remained unclear and follow-up with abdominal computed tomography (CT) scan was not reported. Physical examination at the emergency department revealed yellowish discoloration of the skin, the sclera and the conjunctiva, abdominal tenderness on palpation of the epigastrium and the RUQ without obvious signs of peritoneal irritation and non-tender splenomegaly extending 4–5 cm below the left costal margin. The patient was not febrile and vital signs were within normal limits.

Complete blood count (CBC) showed neutrophilia (82%), lymphopenia (7.6%) and mild eosinophilia (7%) with a normal white blood cell (WBC) count. Liver function tests were abnormal (AST, ALT and γ GT values were 175, 194 and 421 U/L, respectively) and jaundice was confirmed by elevated total and direct bilirubin levels (6.72 and 4.92 mg/dL, respectively), suggesting possible obstruction of the biliary tract. The initial suggestion was further investigated by an upper abdominal ultrasound which revealed a multilocular cystic mass with areas of calcification in the remaining part of the right liver lobe, along with dilatation of the intrahepatic biliary ducts and the common bile duct (CBD) up to 9 mm, and splenomegaly. Based upon these findings, the patient was hospitalized for further investigation. On the second day of hospitalization, eosinophilia was established (19.4%) and clinical condition remained unaltered with the exception of intermittent fever. Endoscopic retrograde cholangiopancreatography (ERCP) was selected as the appropriate method to clarify the cause of extrahepatic biliary obstruction. The findings included dilatation of the common bile duct and presence of hydatid daughter cysts within the CBD. Endoscopic sphincterotomy was performed at the same time and daughter cysts were captured and removed from the proximal part of the duodenum with the use of an endoscopic basket. ERCP also confirmed the presence of an intrahepatic cavity communicating with the right hepatic duct. The patient showed significant clinical and laboratory improvement post-ERCP and underwent an abdominal CT scan which is presented in figure 1. The presence of air (black arrows) indicates the formation of a cystobiliary fistula and the success of endoscopic sphincterotomy. The patient was discharged a few days later with the prescription of appropriate antihelminthic medication.

Comment

Cystic echinococcosis (CE), caused by the tapeworm Echinococcus granulosus, is endemic in Mediterranean countries, the Middle East, South America, South Africa and Oceania. The liver is the most common organ involved, followed by the lungs, accounting both for 90% of cases. CE produces symptoms by

ARCHIVES OF HELLENIC MEDICINE 2008, 25(4):541
ΑΡΧΕΙΑ ΕΛΛΗΝΙΚΗΣ ΙΑΤΡΙΚΗΣ 2008, 25(4):541

**N. Karydis,
L. Lekakos,
P. Katsaronis,
G. Tsourouflis,
G. Kouraklis**

*Second Department of Propedeutic
Surgery, Medical School, University
of Athens, "Laiko" General Hospital,
Athens, Greece*

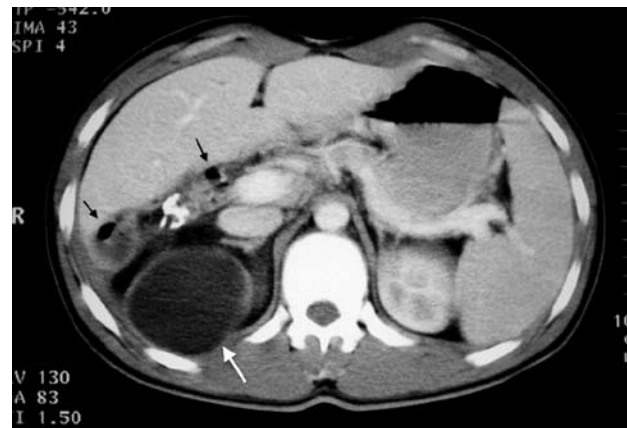


Figure 1. Upper abdominal CT section of a 21-year-old man with a relapsing hydatid cyst showing remnants and calcifications of the cyst in the right liver lobe. A large hydatid cyst of the upper pole of the right kidney (white arrow) was an incidental finding.

mass effect or cyst complications, i.e. infection or rupture. Surgical treatment with total cystectomy remains the gold standard whenever feasible. Rupture of a hepatic hydatid cyst into the biliary tree, spontaneously or after surgical treatment, with the formation of a cystobiliary fistula is not uncommon and may lead to biliary obstruction by daughter cysts, producing cholangitis and, occasionally, severe anaphylactic reactions. Diagnosis of this condition is not always accurate with conventional methods, i.e. ultrasound and CT. In these cases, ERCP is considered the appropriate diagnostic and therapeutic approach, when combined with endoscopic sphincterotomy, offering rapid clinical improvement, low morbidity and shorter hospitalization. Preoperative ERCP facilitates surgery and reduces postoperative bile leakage. In selected cases of biliary obstruction, ERCP may be useful as the definitive treatment. Adjuvant antihelminthic chemotherapy is usually mandatory for eradication, especially when no further surgical treatment is planned.

Corresponding author:

G. Kouraklis, Second Department of Propedeutic Surgery, Medical School, University of Athens, "Laiko" General Hospital, 17 Agiou Thoma street, GR-115 27 Athens, Greece, Tel.: +30210 7456346
e-mail: gkouraklis@hotmail.com

Diagnosis: Hydatid cyst-intestinal rupture