

CONTINUING MEDICAL EDUCATION ΣΥΝΕΧΙΖΟΜΕΝΗ ΙΑΤΡΙΚΗ ΕΚΠΑΙΔΕΥΣΗ

Endocrinology Quiz - Case 2

A 24-year-old woman presented to the Endocrinology Unit because of menstrual irregularities and hirsutism. Patient's symptoms started five years ago, after a moderate increase in her weight (8 kg). She reported that menstruation occurred at sixty days intervals or more, whereas her menstrual cycle was normal before. In addition, hirsutism was developed at face, chest and abdomen, progressively increasing, as well as acne of the face, chest and back. Polycystic ovarian syndrome was diagnosed and she was prescribed oral contraceptive pills for a year, which was discontinued due to skin rash (as she mentioned). Since then she has had menses only after taking progesterone pills. From her medical history, allergic asthma is mentioned, treated with terbutaline on regular basis and hypothyroidism. From her family history, her father suffers from dyslipidemia and high blood pressure.

Physical examination revealed a height of 167 cm and weight of 91,4 kg with a BMI of 39 kg/cm² and a WHR of 0,98. BP was 140/100 mmHg and HR was 84/min. Ferriman-Gallwey score was 15, indicating significant hirsutism. The patient had oily skin and acne at the face, chest and back. She had acanthosis nigricans and acrochordones (skin tags) at the nape of the neck and axilla (fig. 1). Striae were not identified. The thyroid gland was palpated soft, without nodules. The liver was not palpable. There were no other significant findings.

Laboratory testing revealed elevated SGPT (62 IU/L) and triglycerides (388 mg/dL) and low HDL (42 mg/dL). Total and free testosterone were elevated at 132 ng/dL (0-80) and 3,5 pg/mL (0,15-3,17) respectively, SHBG was low at 11,8 nmol/L. Δ4-A was mildly elevated at 3,9 ng/mL (0,3-3,3). TSH was elevated at 6,55 miu/mL. FSH, LH, DHEA-S, 17-OH PRG, PRL were within the normal range. Transabdominal ultrasound revealed bilaterally enlarged ovaries (R: 14cc, L: 16,6 cc) with polycystic morphology. Results on oral glucose tolerance test (OGTT) are depicted on figure 2.

Differential diagnosis includes Cushing's syndrome, late-onset congenital adrenal hyperplasia, androgenizing tumor of adrenal or ovarian origin, acromegaly and HAIR-AN syndrome. Acanthosis nigricans as presenting symptom can be associated with malignancies (commonly stomach adenocarcinoma) and a significant number of nonmalignant conditions (acromegaly, Addison's disease, Cushing's syndrome and HAIR-AN syndrome).

Comment

This syndrome is an acronym for a multisystem disorder in women that consists of hyperandrogenism (HA), insulin resistance (IR) and acanthosis nigricans (AN). About 1-3% percent of women with hyperandrogenism are thought to have this condition, with many cases remaining undiagnosed. The underlying molecular defect is unknown (in some cases a marked decrease of white blood cells insulin receptors has been documented). Keratinocytes stimulation by high insulin levels probably induces formation of the acanthosis nigricans lesions.

Corresponding author:

E. Diamanti-Kandarakis, National and Kapodistrian University of Athens, School of Medicine, First Department of Internal Medicine, "Laiko" General Hospital, GR-115 27 Athens, Greece
e-mail: akandar@otenet.gr

ARCHIVES OF HELLENIC MEDICINE 2007, 24(6):634
ΑΡΧΕΙΑ ΕΛΛΗΝΙΚΗΣ ΙΑΤΡΙΚΗΣ 2007, 24(6):634

X. Xyrafis,
S. Livadas,
G. Boutzios,
E. Tantalaki,
F. Economou,
M. Xristou,
X. Xristakou,
E. Palioura,
C. Kouskouti,
E. Kandaraki,
G. Tsagkaraki,
E. Diamanti-Kandarakis

First Department of Internal Medicine,
Endocrine Section, University of
Athens, "Laiko" General Hospital,
Athens, Greece

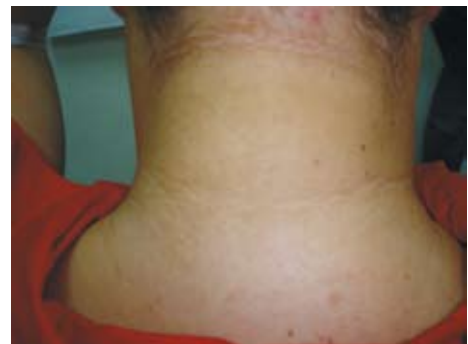

Figure 1.

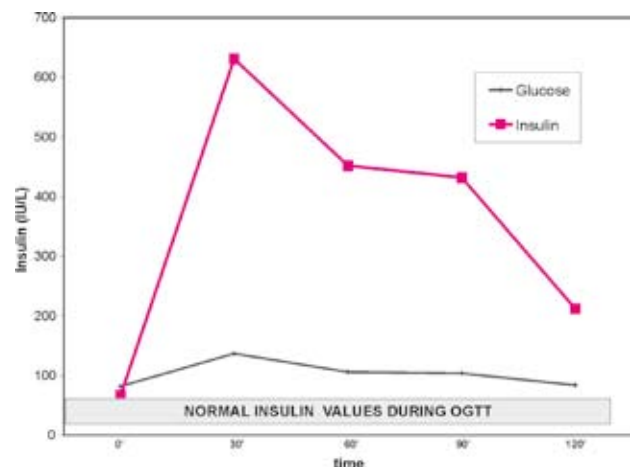


Figure 2.

Diagnosis: HAIR-AN syndrome