

CONTINUING MEDICAL EDUCATION ΣΥΝΕΧΙΖΟΜΕΝΗ ΙΑΤΡΙΚΗ ΕΚΠΑΙΔΕΥΣΗ

Hematology Quiz - Case 1

A 72-year-old man with thrombocytosis was referred to our Department in September 2006 with a 4-month history of skin lesions in lower extremities.

In March 1994, thrombocythemia was diagnosed and the patient was treated with low dose aspirin for the following 4 years as the platelet count ranged between 680 and $800 \times 10^9/l$ and he had no other predisposing factors for thrombosis (no hypertension or diabetes mellitus and no history of deep venous or arterial thrombosis).

In June 1998, the patient had a platelet count of more than $1500 \times 10^9/l$ and was switched to hydroxyurea. At the same time he had a bone marrow trephine biopsy which showed no transformation of the disease in another chronic myeloproliferative disorder or acute leukemia. The bcr-abl test was negative. After 2 months of treatment with 1.5 g/day the platelet count was again $670 \times 10^9/l$ (Figure 1). Patient continued on the same dose until September 2006.

During this period he was under close medical monitoring as an outpatient. In September 2006, a lichen planus-like dermatitis appeared on the lower

ARCHIVES OF HELLENIC MEDICINE 2007, 24(4):401
ΑΡΧΕΙΑ ΕΛΛΗΝΙΚΗΣ ΙΑΤΡΙΚΗΣ 2007, 24(4):401

J. Meletis,
A. Sarantopoulos,
S. Masouridi,
M. Moschogianni,
C. Bomboris,
S. Bouros,
M. Tsironi,
K. Korovesis,
E. Variami,
N. Viniou,
E. Terpos

*First Department of Internal
Medicine, National and Kapodistrian
University of Athens, School of
Medicine, Laiko General Hospital,
Athens, Greece*

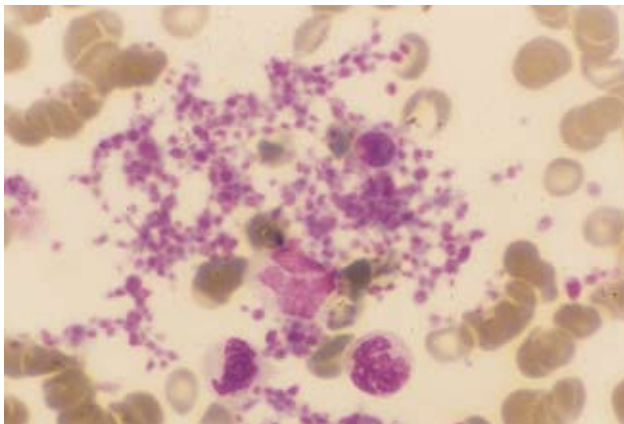


Figure 1.

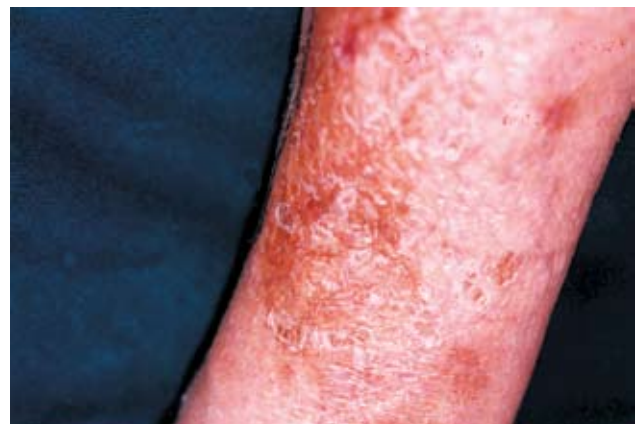

Figure 2.

extremities, which progressively worsened to hyperkeratosis over the following months (Figure 2). A histopathological examination of a skin biopsy documented polymorphonuclear infiltrate in the papillary and reticular dermis, with dilatation of the dermal vessels. Antiskin antibodies determined by indirect immunofluorescence and antinuclear antibodies were negative. We decided to stop hydroxyurea and the patient was given anagrelide. There was a dramatic improvement of the skin lesions. However due to refractory thrombocytosis (platelet count $> 1000 \times 10^9/l$) hydroxyurea at a dose of 1 g/day was started again in February 2007.

Three months later, the patient presented with anemia (Hb 10.4 g/dl), neutropenia ($2.1 \times 10^9/L$), and multiple keratotic lesions on the dorsum of both hands and in the lower extremities. He had also generalized xerosis, erythema of the face, and skin

hyperpigmentation in several areas. A skin biopsy from the keratotic lesions showed the presence of lichen planus.

Hydroxyurea was immediately withdrawn and in several weeks later, we observed a clear improvement in the keratotic skin lesions, and an improvement in blood cell counts. Over the following 2 months, a slow but progressive improvement in the skin lesions led to their healing, while a good clinical and hematological control was obtained by using low busulfan dose.

Corresponding author:

J. Meletis, National and Kapodistrian University of Athens, School of Medicine, First Department of Internal Medicine, Laiko General Hospital, Athens, Greece
e-mail: imeletis@cc.uoa.gr

Diagnosis: Essential thrombocythemia, hydroxyurea inducing hyperkeratosis skin lesions.
